



# PUSHPANJALI HOSPITAL



(A Unit of Pushpanjali Medicare Pvt. Ltd.)

Rajesh Pilot Chowk, Garhi Boini Road, Rewari-123401 (Haryana), India

Phone No +91-1274-263300, 260021

E-mail : pushpanjalihospitalrewari@gmail.com, CIN: U85110DL1987PTC207727

Ref No.	PDC/USG/IPT/UHID056285	Date	15-02-2025
Patient's Name	Mrs. Kusum	Age & Sex	40Y/F
Referred By	Dr. Neeraj	Test Done	USG-


## ULTRASOUND REPORT OF RIGHT BREAST

*Right breast was examined using a linear probe.*

- An oval, non parallel, circumscribed, hypoechoic mass with no posterior features measuring 15x15x17mm is seen at 9 O' Clock position 2cm away from NAC and 9mm deep to skin surface likely – Fibroadenoma.
- Nipple areolar complex appears normal.
- The axillary tails are unremarkable.
- No obvious lymphnode is noted in right axilla.

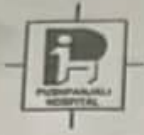### OPINION:

- Right breast BIRADS- 3.

  
Dr. Navdeep  
MBBS MD (Radiodiagnosis)  
Consultant Radiologist







# PUSHPANJALI HOSPITAL

(A Unit of Pushpanjali Medicare Pvt. Ltd.)

Rajesh Pilot Chowk, Garhi Bolni Road, Rewari-123401 (Haryana), India

Phone No +91-1274-263300, 260021

E-mail : pushpanjalihospitalrewari@gmail.com, CIN: U85110DL1987PTC207727



## HISTO PATHOLOGY REQUISITION SLIP

Dr. [Signature]

Date... 15-2-21

Name... Mrs. Kusum [Signature] [Signature]

Age... 40 y Sex... F Address... Rewari (Zalaha) Road Vikash

Admission No... [Signature]

UHID 056285  
11447



972914871

Specimen..... Site.....

Brief Relevant Clinical History

(R) Breast fibroadenoma

Brief Operative Note

Relevant Special Investigation

## CYTOLOGY REQUISITION SLIP

Gynecology Papsmear

Chief Finding and History..... LMP / An

Pre / Post Menopausal / Suspicious Lesion / Other

Sample

Post fornix, Lat Vag wall / endo Cervix

[Signature]

Ref. Dr.....