



PUSHPANJALI HOSPITAL



(A Unit of Pushpanjali Medicare Pvt. Ltd.)
 Rajesh Pilot Chowk, Garhi Bolni Road, Rewari-123401 (Haryana), India
 Phone No +91-1274-263300, 260021
 E-mail : pushpanjalihospitalrewari@gmail.com, CIN: U85110DL1987PTC207727

HISTO PATHOLOGY REQUISITION SLIP


Consultant: Dr. NIGRAJ

Date: 05/02/2025

Name: Mrs. MUKESH w/o HANUMAN

Age: 52 yrs Sex: female Address: Vill. Khairana

UHID - 168089, IPD - 24-11-092, Mobile - 7056015834
Cat - A/B



Specimen: Site:

Brief Relevant Clinical History

Cat Bladder

Brief Operative Note

Any Relevant Special Investigation

CYTOLOGY REQUISITION SLIP

Cytology Papsmear

Clinical Finding and History.....LMP / Any other

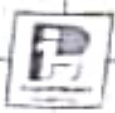Normal / Post Menoposal / Suspicious Lesion / Other

Site of Sample

Cervix / Post fornix, Lat Vag wall / endo Cervix

Ref. Dr.....





PUSHPANJALI HOSPITAL



(A Unit of Pushpanjali Medicare Pvt. Ltd.)
 Rajesh Pilot Chowk, Garhi Bolni Road, Rewari-123401 (Haryana), India
 Phone No. +91-1274-203300, 200021
 E-mail: pushpanjalihospitalrewari@gmail.com. CIN: U85110DL1987PTC207727

Patient Name: Mrs. ANUSHKA UHID No: 1630081 IPD No: 24-1107
 a/c: 504/f Bed No: DDA 4/2.25 DOS: 5/02/25

OPERATION THEATRE NOTES

Surgeon in-charge: Dr. NEERAJ Anesthetist: Dr. MOHIT ARORA
 Assistant Surgeon: OT Technician: Mrs. SUKHVINDA
 Ref: Mr. SURESH K. SINGH Type of Anaesthesia: General ANAESTHETIC
 Pre-operative Diagnosis: SYMPTOMATIC GALLSTONE DISEASE
 Intra-operative Diagnosis: LAP CHOLECYSTECTOMY
 Patient Name: Operation Started at: Operation Finished at: Duration: Whome: Surgeon:

Notes:

- OT Findings -
1. GB distended, wall thickness (w)
 2. Multiple stones in GB lumen
 3. Cystic duct and artery clipped
 4. Calot's triangle anatomy (w)

Pathology (if any): GB

Condition:

Surgeon's Signature

Date & Time

(am / pm)

OR

ULTRASOUND REPORT

27 January 2025

Liver - normal in size shows diffuse fatty infiltration. IHD biliary canaliculi & vascular system normal. no space occupying lesion seen in liver portal vein normal in caliber.

GB - partially contracted, wall not thickened, no pericholecystic fluid, small echogenic foci embedded in anterior wall giving comet tail artifacts [cholesterolosis vs adenomyomatosis], no calculus seen.

CBD - not dilated.

Pancreas - normal in size, anatomy & echotexture.

Spleen - normal.

Right kidney - measure 97x44mm, normal in size and echotexture, small calyceal concretion seen pelvicalyceal system normal, no evidence of hydronephrosis seen.

Left kidney - measure 102x49mm, normal in size & echotexture, small calculus size 3.5mm seen in upper calyx pelvicalyceal system normal, no evidence of hydronephrosis seen.

UB - distended, wall not thickened, no calculus seen.

Uterus - anteverted, normal size & echotexture, endometrial thickness normal, no space occupying lesion seen in uterus, IUCD in situ and normal placed.

Ovaries - mild voluminous in size, normal in echotexture, small follicles in ovary.

POD - minimal fluid in POD.

RIF - appendix not visible on USG at present.

Gut loops - normal in course and caliber showing peristalsis.

No free fluid in abdomen and pelvis.

mp

fatty liver [grade I]

small echogenic foci embedded in anterior wall of GB giving comet tail artifacts mention above [cholesterolosis vs adenomyomatosis]

small nonobstructive left renal calculus

right renal concretion

adv: CBC, LFT, CT abdomen & please correlate clinically

Dr. Ramani Bhutani
MD [Radio-Diagnosis]

[Signature]
Dr. Deepak Bangiya
MD [Radio-Diagnosis]
HMC NO. 6825

ALL FINDINGS SHOULD BE CORRELATED WITH CLINICAL & LAB. FINDINGS.
(NOT VALID FOR MEDICO-LEGAL USE)