





# PUSHPANJALI HOSPITAL

(A unit of Pushpanjali Medicare Pvt. Ltd.)

Rajesh Pilot Chowk, Garhi Bolni Road, Rewari - 123 401 (Haryana), India

Phone: +91-1274-260021, 260521, 260500

Email: pushpanjalihospitalrewari@gmail.com

CIN : U85110DL1987PTC207727

## HISTO PATHOLOGY REQUISITION SLIP

Date: 6/8/20

Name: Mrs. Smt Ramkala V/O DHARAMPAL

Age: 65y Sex: F Address:

155124  
4580

Admission No: 941675

Specimen: Site:



Brief relevant Clinical History

Hemorrhoids

Brief Operative Note

Any Relevant Special Investigation

## CYTOLOGY REQUISITION SLIP

Cytology Papsmear

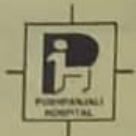Clinical Finding and History..... LMP

Normal / Post Menoposal / Suspicious Lesion / Other

Site of Sample

Cervix / Post fornix, Lat Vag wall / endo Cervix

Ref. Dr.....



# PUSHPANJALI HOSPITAL



(A Unit of Pushpanjali Medicare Pvt. Ltd.)  
Rajesh Pilot Chowk, Garhi Bolni Road, Rewari-123401 (Haryana), India  
Phone No +91-1274-263300, 260021  
E-mail : pushpanjalihospitalrewari@gmail.com, CIN: U85110DL1987PTC207727

Patient Name: Mrs. Smt. Rom/cala UHID No. : 155124 IPD No. : 4580  
Age / Sex: 65y/f Bed No. : ..... D.O.A. 6/8/24 D.O.S. 6/8/24

## OPERATION THEATRE NOTES

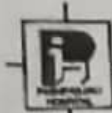Surgeon In-charge : ..... Anesthetist : .....  
Assistant Surgeon : ..... OT Technician : .....  
OT Staff : ..... Type of Anaesthesia : .....  
Pre-Operative Diagnosis : HAEMORRHOIDS  
Post - Operative Diagnosis : .....  
Procedure Name : STAPLER HAE-MORRHOIDECTOMY DONE  
Operation Started at : ..... Operation Finished at : ..... Duration : .....  
Sponge Count : ..... Whome : .....

### Operative Notes :

OT Mrs.  
1. Circumferential haemorrhoids  
2. Haemorrhoidectomy done using  
PPH stapler (prosec) @  
5 and 7 o'clock position

Organ Exploded : .....  
Specimen Sent for histopathology (if any) : .....  
Immediate post-operative condition : .....

Surgeon's Signature : [Signature]  
Date & Time : ..... (am / pm)



# PUSHPANJALI HOSPITAL



(A Unit of Pushpanjali Medicare Pvt. Ltd.)

Rajesh Pilot Chowk, Garhi Bolni Road, Rewari-123401 (Haryana), India

Phone No +91-1274-263300, 260021

E-mail : pushpanjalihospitalrewari@gmail.com, CIN: U85110DL1987PTC207727

Ref No.	PDC/USG/OPC/UHID: 25074	Date	15-04-2024
Patient's Name	Mrs. Ram Kala	Age & Sex	64Y/F
Referred By	Dr. Hemant Yadav	Test Done	USG-

## ULTRASOUND REPORT OF WHOLE ABDOMEN

Liver is normal in size and echo-texture. No obvious focal lesion is seen in liver parenchyma. Intra hepatic biliary channels are not dilated. Portal vein is normal. The CBD is not dilated.

Gall bladder is partially distended. A floating calculus of size 12.3mm is noted in lumen of gall bladder.

Pancreas is normal in size & echotexture with no e/o focal lesion.

Spleen is normal in size and echotexture. No focal lesion is seen.

Right Kidney is normal in size, shape & echotexture. Cortico-medullary differentiation is well maintained. No e/o calculus or hydronephrosis is seen on right side.

Left Kidney is normal in size, shape & echotexture. Cortico-medullary differentiation is well maintained. No e/o calculus or hydronephrosis is seen on left side.

Urinary bladder is well distended. The lumen is echofree with no e/o any calculus or mass lesion.

UTERUS is postmenopausal in appearance.


No e/o ascites seen.

No e/o obvious abdominal lymphadenopathy is seen.

No USG e/o appendicitis is seen.

**IMPRESSION : Cholelithiasis.**

Adv: clinical correlation.

  
 Dr. Ritesh Garg  
 MBBS MD (Radiodiagnosis)  
 Consultant Radiologist

