

PUSHPANJALI HOSPITAL

(A unit of Pushpanjali Medicare Pvt. Ltd.)

Rajesh Pilot Chowk, Garhi Bolni Road, Rewari - 123 401 (Haryana), India

Phone: +91-1274-260021, 260521, 260500

Email: pushpanjalihospitalrewari@gmail.com

CIN : U85110DL1987PTC207727

HISTO PATHOLOGY REQUISITION SLIP

Date... 31/7/20

SUNITA DEVI

Dr Harpal Singh

SSY

Sex F

Address.....

154992

Admission No.....

94660

4317



11856657

Site.....

Relevant Clinical History

Gall Bladder

Operative Note

Relevant Special Investigation

CYTOLOGY REQUISITION SLIP

Cytology Papsmear

Final Finding and History.....

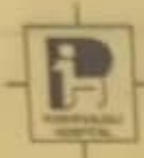LM

Pre / Post Menopausal / Suspicious Lesion / Other

Sample

Post fornix, Lat Vag wall / endo Cervix





PUSHPANJALI HOSPITAL



(A Unit of Pushpanjali Medicare Pvt. Ltd.)

Rajesh Pilot Chowk, Garhi Bolni Road, Rewari-123401 (Haryana), India

Phone No +91-1274-263300, 260021

E-mail : pushpanjalihospitalrewari@gmail.com, CIN: U85110DL1987PTC207727

Name: Ms. Seemita Devi UHID No: 154992 IPD No: 04317
 Age: 55 Y/A Bed No: _____ D.O.A: 30/7/24 D.O.S: 31/7/24

OPERATION THEATRE NOTES

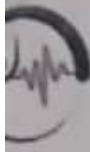Surgeon in-charge: _____ Anesthetist: _____
 Assistant Surgeon: _____ OT Technician: _____
 Staff: _____ Type of Anaesthesia: _____
 Operative Diagnosis: ACUTE CHOLECYSTITIS w/ ERCP STENTING
 Operative Diagnosis: _____
 Procedure Name: LAP CHOLECYSTECTOMY
 Operation Started at: _____ Operation Finished at: _____ Duration: _____
 Page Count: _____ Whome: _____

Operative Notes:

- OT Findings -
1. Omental adhesions noted over GB
 2. Multiple stones in GB lumen
 3. Inflammation over calot's triangle region
 4. Cystic duct and artery clipped

Specimen Exploded: _____
 Specimen Sent for histopathology (if any): GB
 Immediate post-operative condition: _____

Surgeon's Signature: _____
 Date & Time: _____ (am / pm)



PULSE HOSPITAL
More than just treating patients

Dr. Pratibha MD(Radio-Diagnosis)
Ex. SR. Resident RML, New Delhi
Ex. SR. Resident Safdarjung, New Delhi

NAME: Mrs. Sunita Devi
REF. BY.: Dr. Neeraj

AGE / SEX: 54 YRS/ F
DATE: 28/07/2024

ULTRASOUND WHOLE ABDOMEN

Liver is moderately enlarged in size (20cm) and shows grade I fatty changes. No focal lesion is seen in liver parenchyma. Intrahepatic biliary radicals are not dilated. Portal vein is normal in caliber.

Gall bladder is adequately distended. Wall thickness is normal. A large calculus of size 18mm are noted in lumen. Multiple calculi of average size 4-5mm is also noted in lumen.
Common bile duct is normal in caliber (2mm). Visualised lumen is echo free.

Pancreas is normal in size and echotexture. No focal lesion seen.
Spleen is normal in size and echotexture. No focal lesion seen.

Right kidney is normal in size, shape & echotexture. Cortico-medullary differentiation is maintained. No evidence of any hydronephrosis or calculus is seen.

Left kidney is normal in size, shape & echotexture. Cortico-medullary differentiation is maintained. No evidence of any hydronephrosis or calculus is seen.

Urinary bladder is partially distended. Lumen is echo free with no intraluminal pathology.

Uterus is normal according to age (post-menopausal status).


Bilateral adnexa are clear.

No free fluid is seen in the abdomen.
No significant lymphadenopathy is seen in the abdomen.

Impression:

- Cholelithiasis.
- Moderate hepatomegaly with grade I fatty liver.

Kindly correlate clinically.


DR. PRATIBHA CHOUDHARY
MD RADIO-DIAGNOSIS

This is only professional opinion, not a diagnosis. This report is not valid for any medico-legal aspect. USG scan is an investigation and therefore has technical limitations.

www.pulsehospital.org Email Id: hospitalpulse23@gmail.com

Contact No. : 9991259976, Noida Road, Kirti, 122302 (Hr)

