



PUSHPANJALI HOSPITAL

(A unit of Pushpanjali Medicare Pvt. Ltd.)

Rajesh Pilot Chowk, Garhi Bolni Road, Rewari - 123 401 (Haryana), India

Phone: +91-1274-260021, 260521, 260500

Email: pushpanjalihospitalrewari@gmail.com

CIN : U85110DL1987PTC207727

Dr. Kamal

HISTO PATHOLOGY REQUISITION SLIP

Date *26/7/2*

Name *Suresh Bhan* S/o *Naresh Singh*

Age *81y* Sex *M* Address

154710 Admission No.

4192

Specimen Site



Brief relevant Clinical History

TURP chips

Brief Operative Note

Relevant Special Investigation

CYTOLOGY REQUISITION SLIP

Cytology Papsmear

Clinical Finding and History..... LMP /

Pre-menopausal / Post Menopausal / Suspicious Lesion / Other

Site of Sample

Ex / Post fornix, Lat Vag wall / endo Cervix

Ref. Dr.

R. JESH GOYAL

Medical Diagnostic

123401

123401

123401

R. RITU JAIN

MD, MC (Dist. & Genl)

123401

123401

123401

Print Free



K.LAL

ULTRASOUND

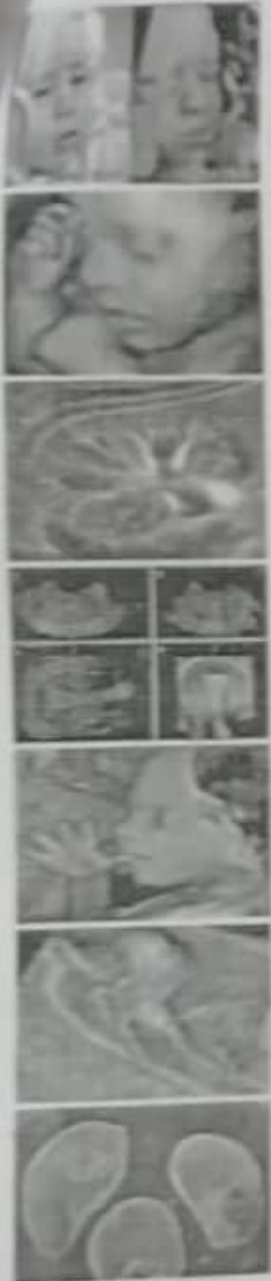
&

IMAGING CLINIC

Patient Name: Suraj Bhan s/o Nar Singh
Age: 80Y/M

Date: 17 July 2024
Ref. By Dr: Kaushal Goyal

ULTRASOUND REPORT (WHOLE ABDOMEN)



Liver: Normal size, shape & outline.
Grade II fatty change seen
Small degenerative cyst seen in right lobe of liver anteromedially measuring 26.6 x 21.6mm.
PV-Normal
CBD - Dilated (7.5mm), however no obvious calculi seen in visualized portion of CBD.
IHBR - Not dilated.

GB: Wall regular & normal thickness.
Couple of large (20mm & 19.4mm) calculi seen in lumen of GB.

Spleen: Normal size, shape & echopattern.

Pancreas: Normal size, shape & echo texture.

Right Kidney: Normal size, shape & outline.
Multiple small & large cortical cysts seen in upper, mid & lower pole region. Largest measures 5.8 x 5.8cm.
Corticomedullary differentiation normal.
No evidence of nephrolithiasis/nephrocalcinosis.
Right kidney shows grade I hydronephrosis

Left Kidney: Normal size, shape & echopattern.
Large cortical cyst seen in lower pole region measuring 6.9 x 6.8cm
Corticomedullary differentiation normal.
No evidence of nephrolithiasis/nephrocalcinosis.
Left kidney shows grade I hydronephrosis

No evidence of obvious abdominal lymphadenopathy.
No evidence of free fluid in abdomen.
No obvious USG s/o acute appendicitis seen.

Urinary Bladder: Walls mildly thickened
Foley's seen in situ.

Prostate: Grossly enlarged in size & measures 6.4 x 5.8 x 5.4cm,
volume - 104cc.

Imp: Cholelithiasis
Mildly thickened UB walls s/o Cystitis / UTI.
Gross prostatic enlargement.

Incidental note is made of dilated LV with poor contractility of LV & increased EDV.

Adv: ECG, ECHO correlation
Urine examination
Clinical correlation

DR. R. JESH GOYAL
RADIOLOGIST

Equipped with
VOLISON E8
Voluson E8 Radiance
Digital X-Ray



21, BRASS MARKET, REWARI-123401 (HARYANA) PH. : 01274-222915, 9902112115

In case of ultrasound/ultrasonography please contact the Radiologist immediately. All important notifications can not be delivered by ultrasound. For more information please visit our website.

UHD No. 154710



PUSHPANJALI HOSPITAL



(A Unit of Pushpanjali Medicare Pvt. Ltd.)
Rajesh Pilot Chowk, Garhi Bolni Road, Rewari-123401 (Haryana), India
Phone No +91-1274-263300, 260021
E-mail : pushpanjalihospitalrewari@gmail.com, CIN: U55110DL1987PTC207727

Patient Name: Mr. Sarvag Bhan UHID No. 154710 IPD No. 04192
Age / Sex: 81 ym Bed No. DOA 26-7-24 DOS 26-7-24

OPERATION THEATRE NOTES

Surgeon In-charge: Dr. Kamal Anesthetist: Dr. Mohit
Assistant Surgeon: Dr. Yogesh OT Technician:
OT Staff: Type of Anaesthesia: SA
Pre-Operative Diagnosis: BPE
Post-Operative Diagnosis:
Procedure Name: TURP
Operation Started at: Operation Finished at: Duration:
Sponge Count: Whome:

Operative Notes: findings: Grade III obstructive Prostatomegaly
Procedure: After P&D of Parts, LASP, Cystoscopy done. Above mentioned findings are noted. Resection of Prostate done with bipolar resectoscope. TURP chips retrieved using Ellik's evacuator. Complete Hemostasis ensured. 24 hr 3-way Foley's catheterization done & NS Irrigation started.

Organ Explored:
Specimen Sent for histopathology (if any): TURP chips
Immediate post-operative condition: Good.

Surgeon's Signature:

Date & Time: (am / pm)