

PUSHPANJALI HOSPITAL

(A unit of Pushpanjali Medicare Pvt. Ltd.)

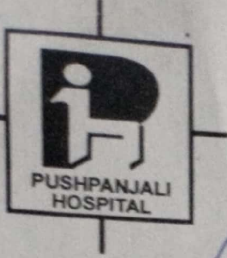
Rajesh Pilot Chowk, Garhi Bolni Road, Rewari - 123 401 (Haryana), India

Phone: +91-1274-260021, 260521, 260500

Email: pushpanjalihospitalrewari@gmail.com

CIN : U85110DL1987PTC207727

HISTO PATHOLOGY REQUISITION SLIP



Date... 17-7-24

Name Mr. Umesh Kumar S/o Devender Singh

Age 55 YR Sex R Address 344 B Sub Housing Road

Admission No. Dr. Umesh Kumar

9728672011

Specimen UAIQ - 153955 Site 03782 Gall bladder

Brief relevant Clinical History

Acute cholecystitis

Brief Operative Note

Any Relevant Special Investigation

CYTOLOGY REQUISITION SLIP

Cytology Papsmear

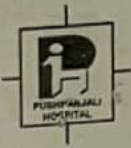Clinical Finding and History..... LMP / Any other

Normal / Post Menoposal / Suspicious Lesion / Other

Site of Sample
Cervix / Post fornix, Lat Vag wall / endo Cervix

Ref. Dr.....





PUSHPANJALI HOSPITAL



(A Unit of Pushpanjali Medicare Pvt. Ltd.)

Rajesh Pilot Chowk, Garhi Bolni Road, Rewari-123401 (Haryana), India

Phone No +91-1274-263300, 260021

E-mail : pushpanjalihospitalrewari@gmail.com, CIN: U85110DL1987PTC207727

Ref No.	PDC/USG/IPT/UHID153955	Date	15-07-2024
Patient's Name	Mrs. Umesh Devi	Age & Sex	55Y/F
Referred By	Dr. Neeraj	Test Done	USG-

ULTRASOUND REPORT OF WHOLE ABDOMEN

Liver is normal in size and echo-texture. No obvious focal lesion is seen in liver parenchyma. Intra hepatic biliary channels are not dilated. **Portal vein** is normal. **The CBD** is not dilated.

Gall bladder is partially distended. **Multiple floating calculi** are noted in lumen of gall bladder, largest of size 21.7mm.

Pancreas is normal in size & echotexture with no e/o focal lesion.

Spleen is normal in size and echotexture. No focal lesion is seen.

Right Kidney is normal in size, shape & echotexture. Cortico-medullary differentiation is well maintained. No e/o calculus or hydronephrosis is seen on right side.

Left Kidney is normal in size, shape & echotexture. Cortico-medullary differentiation is well maintained. No e/o calculus or hydronephrosis is seen on left side.

Urinary bladder is well distended. The lumen is echofree with no e/o any calculus or mass lesion.

Uterus is retroverted however appears normal. Myometrium shows normal echo-pattern. No focal space occupying lesion is seen. Endometrial echo is normal. Endometrial thickness is 5 mm.

Both ovaries are visualised and are normal. No adnexal mass is seen.

No free fluid is seen in pouch of douglas.

No e/o ascites seen.

No e/o obvious abdominal lymphadenopathy is seen.

No USG e/o appendicitis is seen.

IMPRESSION: Cholelithiasis.

Adv: clinical correlation.

Dr. Ritesh Garg
MBBS MD (Radiodiagnosis)
Consultant Radiologist





PUSHPANJALI HOSPITAL

(A Unit of Pushpanjali Medicare Pvt. Ltd.)

Rajesh Pilot Chowk, Garhi Bolni Road, Rewari-123401 (Haryana), India

Phone No +91-1274-263300, 260021

E-mail : pushpanjalihospitalrewari@gmail.com, CIN: U85110DL1987PTC207727



Patient Name : Mr Umesh Dew UHID No : 153955 IPD No : 03782

Sex : 5546 Bed No : 82 D.O.A. 15-7-24 D.O.S. 17-7-24

OPERATION THEATRE NOTES

Surgeon In-charge : Anesthetist :

Assistant Surgeon : OT Technician :

OT Staff : Type of Anaesthesia :

Pre-Operative Diagnosis : ACUTE CHOLECYSTITIS

Post - Operative Diagnosis :

Procedure Name : LAP CHOLECYSTECTOMY

Operation Started at : Operation Finished at : Duration :

Sponge Count : Whome :

Operative Notes :

- OT Findings -
1. Dense omental adhesions noted over GB fundus
 2. GB distended, wall thickened
 3. Calot's triangle region inflammation and adhesions seen
 4. GB lumen filled with multiple stones
 5. Cystic duct ϕ - wide, tied with silk 1-0 endoloop

Organ Explored :

Specimen Sent for histopathology (if any) :

Immediate post-operative condition :

Surgeon's Signature :

Date & Time : (am / pm)