



PUSHPANJALI HOSPITAL

(A unit of Pushpanjali Medicare Pvt. Ltd.)

Rajesh Pilot Chowk, Garhi Bolni Road, Rewari - 123 401 (Haryana), India

Phone: +91-1274-260021, 260521, 260500

Email: pushpanjalihospitalrewari@gmail.com

CIN : U85110DL1987PTC207727

DR Kamal

HISTO PATHOLOGY REQUISITION SLIP


Date 17-7-24

Name Mr Phasal Ram S/o Raj Bah

Age 78y Sex M Address Kakkala

UAD 15405 Admission No 9350524482

Specimen 03024 Site 9466665886



Brief relevant Clinical History

Brief Operative Note

TURP chips

Any Relevant Special Investigation

CYTOLOGY REQUISITION SLIP

Cytology Papsmear

Clinical Finding and History..... LMP / Any other

Normal / Post Menoposal / Suspicious Lesion / Other

Site of Sample Cervix / Post fornix, Lat Vag wall / endo Cervix

Ref. Dr. Yogesh



PUSHPANJALI HOSPITAL



(A Unit of Pushpanjali Medicare Pvt. Ltd.)

Rajesh Pilot Chowk, Garhi Bolni Road, Rewari-123401 (Haryana), India

Phone No +91-1274-263300, 260021

E-mail : pushpanjalihospitalrewari@gmail.com, CIN: U85110DL1987PTC207727

| | | | |
|----------------|------------------------|-----------|------------|
| Ref No. | PDC/USG/OPC/UHID072964 | Date | 11-07-2024 |
| Patient's Name | Mr. Phusal Ram | Age & Sex | 81 Y/M |
| Referred By | Dr. Kamal | Test Done | USG- |

ULTRASOUND REPORT OF WHOLE ABDOMEN

Liver is normal in size and shows **grade I fatty infiltration**. No obvious focal lesion is seen in liver parenchyma. Intra hepatic biliary channels are not dilated. **Portal vein** is normal. **The CBD** is not dilated.

Gall bladder is partially distended. No e/o any obvious calculus or mass lesion is seen.

Pancreas is normal in size & echotexture with no e/o focal lesion.

Spleen is normal in size and echotexture. No focal lesion is seen.

Small simple cysts are seen in **bilateral kidneys**, largest of size 51x46mm at lower pole of left kidney.

Right Kidney is normal in size (8.2x3.8cm) and shows **grade I raised cortical echotexture**. Cortico-medullary differentiation is well maintained. No e/o calculus or hydronephrosis is seen on right side.

Left Kidney is normal in size (8.3x3.7cm) and shows **grade I raised cortical echotexture**. Cortico-medullary differentiation is well maintained. No e/o calculus or hydronephrosis is seen on left side.

Urinary bladder is adequately distended. Foley's bulb is seen in-situ.

Prostate is moderately enlarged in size volume 89cc.

No e/o ascites or free fluid seen.

No e/o obvious abdominal lymphadenopathy is seen.

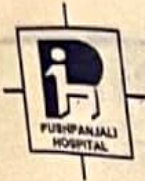No USG e/o appendicitis is seen.

IMPRESSION :

- **Grade I fatty liver.**
- **Bilateral chronic medical renal disease.**
- **Bilateral renal simple cysts.**
- **Moderate prostatomegaly.**

Adv: clinical correlation.

Dr. Ritesh Garg
MBBS MD (Radiodiagnosis)
Consultant Radiologist



PUSHPANJALI HOSPITAL



(A Unit of Pushpanjali Medicare Pvt. Ltd.)

Rajesh Pilot Chowk, Garhi Bolni Road, Rewari-123401 (Haryana), India

Phone No +91-1274-263300, 260021

E-mail : pushpanjalihospitalrewari@gmail.com, CIN: U85110DL1987PTC207727

Name : Mr. Khushal Ram UHID No. : 154005 IPD No. : 03824
 Sex : M Bed No. : D.O.A. : 16-7-24 D.O.S. : 17-7-24

OPERATION THEATRE NOTES

Surgeon In-charge : Dr. Kamal Anesthetist : Dr. Mohit
 Assistant Surgeon : Dr. Yogesh OT Technician :
 Staff : Type of Anaesthesia : SA
 Pre-Operative Diagnosis :
 Post-Operative Diagnosis :
 Procedure Name : TURP
 Operation Started at : Operation Finished at : Duration :
 Sponge Count : Whome :

Operative Notes: Findings: Grade III obstructive Prostatomegaly
Procedure: After TAD of Parts, LASP, Cystoscopy done, above mentioned findings are noted. Resection of Prostate done using Bipolar resectoscope. TURP chips retrieved, using Elik's evacuator. Complete Hemostasis ensured.

Organ Explained :
 Specimen Sent for histopathology (if any) : TURP chips
 Immediate post-operative condition : Good.

Surgeon's Signature : [Signature]
 Date & Time : 17/7/24 (am / pm)