



PUSHPANJALI HOSPITAL

(A unit of Pushpanjali Medicare Pvt. Ltd.)

Rajesh Pilot Chowk, Garhi Bolni Road, Rewari - 123 401 (Haryana), India

Phone: +91-1274-260021, 260521, 260500

Email: pushpanjalihospitalrewari@gmail.com

CIN : U85110DL1987PTC207727

HISTO PATHOLOGY REQUISITION SLIP



Date 12/7/24

Name Sarej Devi S/o Ugo Dharmender Kaur

Age 55Y Sex F Address Rewari

UHID- 153227 Admission No. 8391080808

IPD- 3108

Specimen Site

Ref relevant Clinical History

Gall Bladder

Ref Operative Note

Relevant Special Investigation

CYTOLOGY REQUISITION SLIP

Cytology Papsmear

Clinical Finding and History..... LMP / Any c

Normal / Post Menoposal / Suspicious Lesion / Other

Site of Sample
Pre / Post fornix, Lat Vag wall / endo Cervix

Ref. Dr.....



PUSHPANJALI HOSPITAL



(A Unit of Pushpanjali Medicare Pvt. Ltd.)

Rajesh Pilot Chowk, Garhi Bolni Road, Rewari-123401 (Haryana), India

Phone No +91-1274-263300, 260021

E-mail : pushpanjalihospitalrewari@gmail.com, CIN: U85110DL1987PTC207727

Ref No.	PDC/USG/IPT/UHIDI53227	Date	13-07-2024
Patient's Name	Mrs. Saroj Devi	Age & Sex	55Y/F
Referred By	Dr. Neeraj	Test Done	USG-

ULTRASOUND REPORT OF WHOLE ABDOMEN

Liver is mildly enlarged in size 16.5cm and shows grade I fatty infiltration. No obvious focal lesion is seen in liver parenchyma. Intra hepatic biliary channels are not dilated. Portal vein is normal. The CBD is not dilated.

Gall bladder is partially distended. A floating calculus of size 13.4mm is noted in lumen of gall bladder.

Pancreas is normal in size & echotexture with no e/o focal lesion.

Spleen is normal in size and echotexture. No focal lesion is seen.

Right Kidney is normal in size, shape & echotexture. Cortico-medullary differentiation is well maintained. No e/o calculus or hydronephrosis is seen on right side.

Left Kidney is normal in size, shape & echotexture. Cortico-medullary differentiation is well maintained. No e/o calculus or hydronephrosis is seen on left side.

Urinary bladder is empty.

No e/o ascites seen.

No e/o obvious abdominal lymphadenopathy is seen.

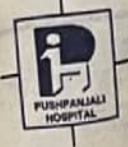No USG e/o appendicitis is seen.

IMPRESSION :

- > Mild hepatomegaly with grade I fatty liver.
- > Cholelithiasis.

Adv: clinical correlation.

Dr. Ritesh Garg
MBBS MD (Radiodiagnosis)
Consultant Radiologist



PUSHPANJALI HOSPITAL

(A Unit of Pushpanjali Medicare Pvt. Ltd.)
Rajesh Pilot Chowk, Garhi Bolni Road, Rewari-123401 (Haryana), India
Phone No +91-1274-263300, 260021
E-mail : pushpanjallhospitalrewari@gmail.com, CIN: U85110DL1987PTC207727



Name: Mrs. Suraj Devi UHID No. : 153224
Bed No. 554/F IPD No. : 3768
D.O.A. 12/07/24 D.O.S. 13/07/24

OPERATION THEATRE NOTES

Surgeon In-charge : Anesthetist :
Assistant Surgeon : OT Technician :

Pre-operative Diagnosis : Type of Anaesthesia :
Operative Diagnosis : ACUTE CHOLECYSTITIS "P" ERCP study status

Procedure Name : LAP CHOLECYSTECTOMY done
Operation Started at : 12:30 Operation Finished at : 1:00P Duration : 30 Minut
Sponge Count : Whome :

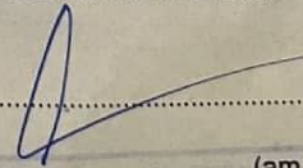
Operative Notes :

OT Findings -

1. GB distended
2. A large stone noted in GB lumen
3. Inflammation seen in Calot's triangle region
4. Cystic duct and artery clipped

Specimen Explained :
Specimen Sent for histopathology (if any) : GB

Immediate post-operative condition :

Surgeon's Signature : 
Date & Time : (am / pm)