

Booking Date 24-May-24

Name: Mrs. NIDHI GULATI

Barcode: 11904664

Patient ID: 012405240235

Age: 53 YRS

Sample Date 24-May-24

Sex: F

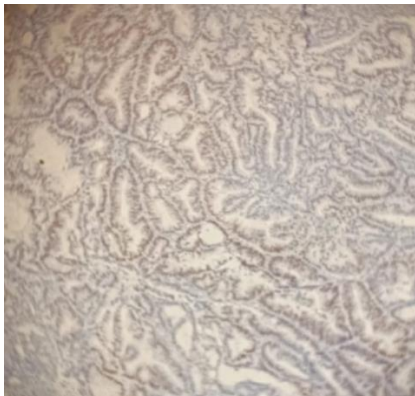
Immunohistochemistry

Clinical Details: Tumor with intramural fibroid and serosa

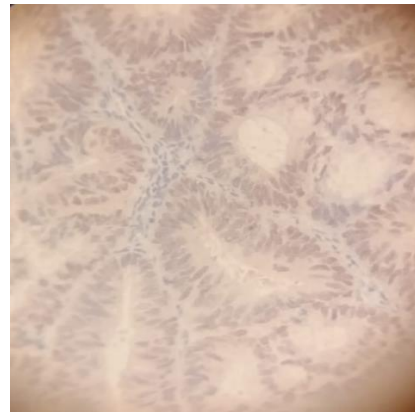
Specimen Details: IHC done on blocks no. A/H/10863/24

Disease: Endometrial cancer

Microscopic Findings:



ER



PR

Microscopic Findings:

Estrogen Receptor α (ER)

- % Cells immunoreactive – 60%
- Intensity- High
- Internal control-Positive
- Interpretation- Positive

Progesterone Receptor (PR)

- % Cells immunoreactive – 75%
- Intensity- High.
- Internal control-Positive
- Interpretation- Positive

•

Results

1. Estrogen Receptor α - Positive
2. Progesterone Receptor- Positive