

**Booking Date** 19/03/2024  
**Name:** RAFEEQA AKHTER SHOPIAN  
**Barcode:** 105200631

**Patient ID:** 042403190008  
**Age:** 44 years

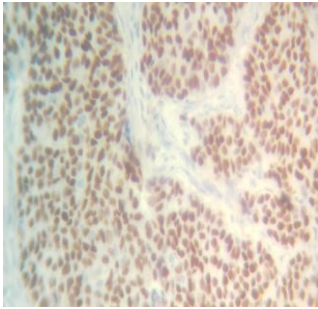
**Sample Date** 19/03/2024  
**Sex:** F

### Immunohistochemistry

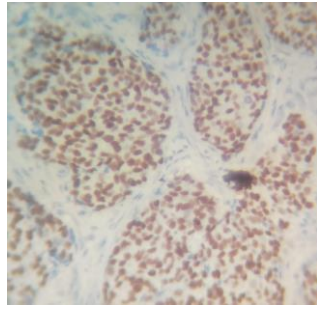
**Clinical Details:** Breast carcinoma

**Specimen Details:** IHC done on blocks no. MOLQ B- 959/24

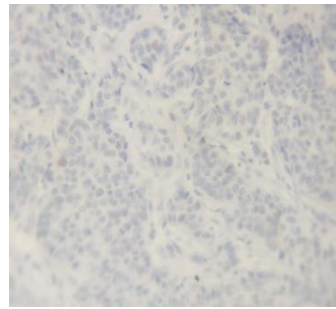
#### Microscopic Findings:



**ER**



**PR**



**HER 2 NEU**

#### Microscopic Findings:

##### **Estrogen Receptor $\alpha$ (ER)**

- % Cells immunoreactive – 90%
- Intensity- High
- Internal control-Positive
- Interpretation- Positive

##### **Progesterone Receptor (PR)**

- % Cells immunoreactive – 85%
- Intensity- High
- Internal control-Positive
- Interpretation- Positive

##### **Her-2/neu**

- Total Score- 0
- Interpretation- Negative

#### **Results**

1. Estrogen Receptor  $\alpha$ - Positive
2. Progesterone Receptor- Positive
3. Her-2/neu- Negative.