

Booking Date 11/03/2024

Patient ID: 042403110001

Reporting Date 13/03/2024

Name: : MUNAZA

Age: 16 years

Sex: F

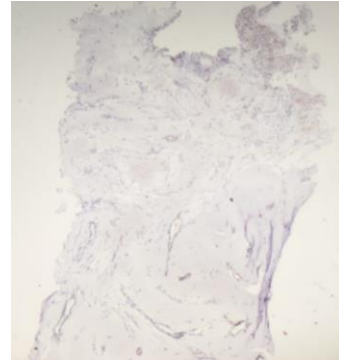
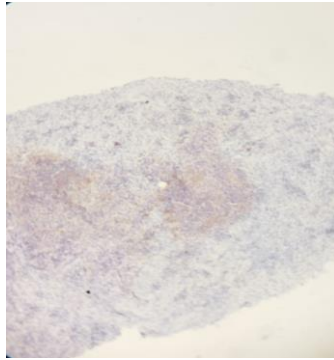
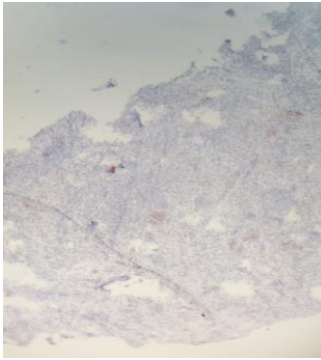
Barcode: 105200550

Immunohistochemistry

Clinical Details: Breast Tissue

Specimen Details: IHC done on blocks no. GK- 6286/24

Microscopic Findings:



ER

PR

HER 2 NEU

Microscopic Findings:

Estrogen Receptor α (ER)

- % Cells immunoreactive – 00%
- Intensity- Score -00
- Total score -00
- Internal control-Positive
- Interpretation- Negative

Result

1. Estrogen Receptor - Negative
2. Progesterone Receptor- Negative
3. Her-2 neu- Negative

Progesterone Receptor (PR)

- % Cells immunoreactive – 00%
- Intensity- score -00
- Total score -00
- Internal control-Positive
- Interpretation- Negative

Her-2 neu

- % Cells immunoreactive -00%
- Intensity-score -00
- Total score -00
- Internal control -Positive
- Interpretation- Negative

Reviewed by



Dr. Gulshan Yadav, MD
Pathology