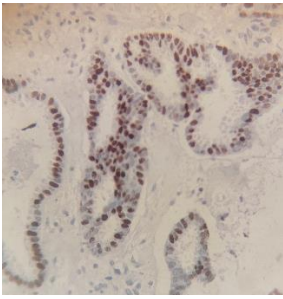

Booking Date 07/02/2024 **Patient ID:** 012402070022 **Reporting Date** 16/02/2024
Name: : BABY KAUR **Age:** 71 years **Sex:** F
Barcode:11059655

Immunohistochemistry No: - MOLQ IHC- 004/24

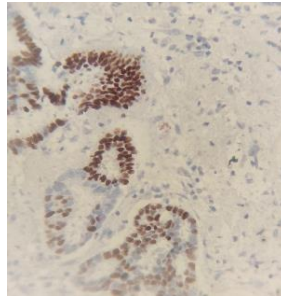
Clinical Details: ? Ca Breast

Specimen Details: IHC done on blocks no. MOLQ B- 348/24

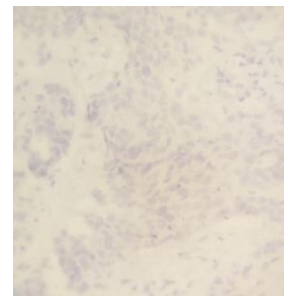
Microscopic Findings:



ER



PR



HER 2 NEU

Microscopic Findings:

Estrogen Receptor α (ER)

- % Cells immunoreactive – 80%
- Intensity- Score -05
- Total score -8/8
- Internal control-Positive
- Interpretation- Positive

Progesterone Receptor (PR)

- % Cells immunoreactive – 50%
- Intensity- score -03
- Total score -6/8
- Internal control-Positive
- Interpretation- Positive

Her-2 neu

- % Cells immunoreactive -00%
- Intensity-score -00
- Total score -00
- Internal control -Positive
- Interpretation- Negative

Result

1. Estrogen Receptor α - Positive
2. Progesterone Receptor- Positive
3. Her-2 neu-Negative

Reviewed by



Dr. Gulshan Yadav, MD
Pathology

MolQ Laboratory (A Unit of Molecular Quest Healthcare Pvt. Ltd.)

Reference Laboratory: 28-29, Sector-18 (P) | Gurgaon, Haryana, 122015 | Phone 0124 - 4307906, Fax 0124 - 4278596 | Email: