

Booking Date 07/02/2024
Name: : BABY KAUR
Barcode:11059655

Patient ID: 012402070022
Age: 71 years

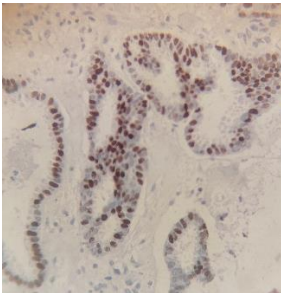
Reporting Date 16/02/2024
Sex: F

Immunohistochemistry No: - MOLQ IHC- 004/24

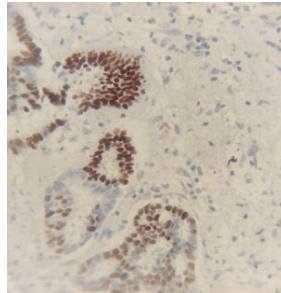
Clinical Details: ? Ca Breast

Specimen Details: IHC done on blocks no. MOLQ B- 348/24
IHC NO - 004/24

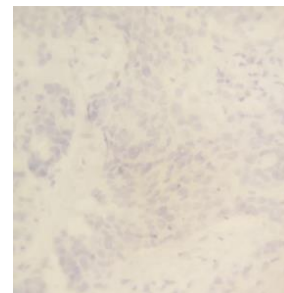
Microscopic Findings:



ER



PR



HER 2 NEU

Microscopic Findings:

Estrogen Receptor α (ER)

- % Cells immunoreactive – 80%
- Intensity- Score -05
- Total score -8/8
- Internal control-Positive
- Interpretation- Positive

Progesterone Receptor (PR)

- % Cells immunoreactive – 50%
- Intensity- score -03
- Total score -6/8
- Internal control-Positive
- Interpretation- Positive

Her-2 neu

- % Cells immunoreactive -00%
- Intensity-score -00
- Total score -00
- Internal control -Positive

- Interpretation- Negative

MolQ Laboratory (A Unit of Molecular Quest Healthcare Pvt. Ltd.)

Reference Laboratory: 28-29, Sector-18 (P) I Gurgaon, Haryana, 122015 I Phone 0124 - 4307906, Fax 0124 - 4278596 I Email:

Booking Date 07/02/2024

Patient ID: 012402070022

Reporting Date 16/02/2024

Name: : BABY KAUR

Age: 71 years

Sex: F

Barcode: 11059655

Result

1. Estrogen Receptor α - Positive
2. Progesterone Receptor- Positive
3. Her-2 neu-Negative

Reviewed by



Dr. Gulshan Yadav, MD
Pathology