

---

**Booking Date** 07/02/2024    **Patient ID:** 012402070022    **Reporting Date** 16/02/2024  
**Name:** : BABY KAUR    **Age:** 71 years    **Sex:** F  
**Barcode:**11059655

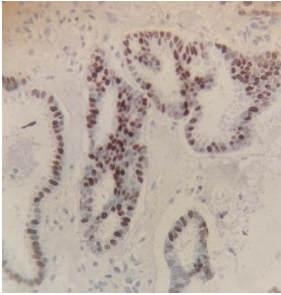
---

**Immunohistochemistry No: - MOLQ IHC- 004/24**

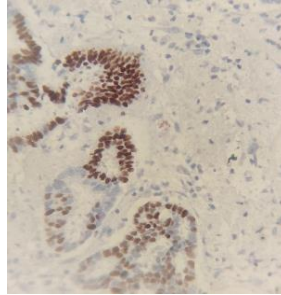
**Clinical Details:** ? Ca Breast

**Specimen Details:** IHC done on blocks no. MOLQ B- 348/24  
**IHC NO** - 004/24

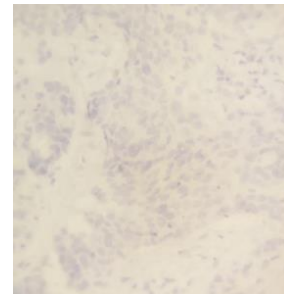
**Microscopic Findings:**



**ER**



**PR**



**HER 2 NEU**

**Microscopic Findings:**

- Interpretation- Negative

**Estrogen Receptor  $\alpha$  (ER)**

- % Cells immunoreactive – 80%
- Intensity- Score -05
- Total score -8/8
- Internal control-Positive
- Interpretation- Positive

**Progesterone Receptor (PR)**

- % Cells immunoreactive – 50%
- Intensity- score -03
- Total score -6/8
- Internal control-Positive
- Interpretation- Positive

**Her-2 neu**

- % Cells immunoreactive -00%
- Intensity-score -00
- Total score -00
- Internal control -Positive

## Result

1. Estrogen Receptor  $\alpha$ - Positive
2. Progesterone Receptor- Positive
3. Her-2 neu-Negative

Reviewed by



**Dr. Gulshan Yadav, MD**  
**Pathology**

Reference Laboratory: 28-29, Sector-18 (P) | Gurgaon, Haryana, 122015 | Phone 0124 - 4307906, Fax 0124 - 4278596 | Email: