

Name of Patient : Mahesh Kumar

Date : 23/01/2024

Age/Gender : 44/M

Barcode : 44240000074

HER2/neu IHC

Human Epidermal Growth Factor Receptor 2 Immunohistochemistry

Specimen Information

Gastric biopsy

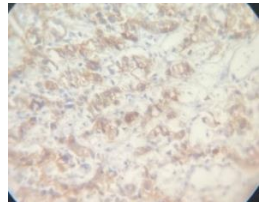
Clinical History

Poorly differentiated adenocarcinomas

Methodology

Immunohistochemistry

Diagnosis

Markers	Results		Interpretation	Image
Her-2/neu	Percentage of cells with uniform intense complete membrane staining	0	Negative	

Comments

HER-2 Significance:

The HER2 gene is responsible for the formation of HER2 Protein, which is a Human growth Factor Receptor. A positive HER2 test result would mean overexpression of Her2 protein and is seen in about 20% of breast carcinomas.

Various studies have shown that these HER2 positive tumours have aggressive growth, metastasize faster and have less favourable prognosis than HER2 negative tumours.

However, they have shown to have good response to AntiHER2 therapy (either monoclonal antibodies or relevant tyrosine kinase inhibitors).

Table: Reporting results of HER2 Testing by Immunohistochemistry(IHC)

Result	Criteria
Negative (Score 0)	No staining observed or Membrane staining that is incomplete and is faint/barely perceptible and within $\leq 10\%$ of tumor cells
Negative(Score 1+)	Incomplete membrane staining that is faint/barely perceptible and within $>10\%$ of tumor cells*
Equivocal (Score 2+)	Weak to moderate complete membrane staining in $>10\%$ of tumor cells or Complete membrane staining that is intense but within $\leq 10\%$ of tumor cells*
Positive (Score 3+)	Complete membrane staining that is intense and $>10\%$ of tumor cells*

* Readily appreciated using a low-power objective and observed within a homogeneous and contiguous population of invasive tumor cells.

Technical Note

1. undefined
2. All immunohistochemistry markers have been evaluated in the context of appropriate positive and negative controls. A result is considered uninterpretable as a result of the type of fixative used (non 10% neutral buffered formalin), time to fixation (> 1 hour), duration of fixation (< 6 hr or > 72 hour), strong decalcification, or inappropriate staining of normal internal or external assay controls. An alternative sample for retesting is then usually recommended.
3. Assay has been performed on formalin fixed paraffin embedded tissue, using the polymer based detection system for Immunohistochemistry studies.
4. Cold ischemia and fixation time: Not known
5. Internal control ER: Present and stain as expected
6. Internal control PR: Absent

Disclaimer : These assays have not been validated on decalcified specimens.

References

1. Wolff AC, Hammond MEH, Allison KH, et al. HER2 testing in breast cancer: American Society of Clinical Oncology/College of American Pathologists clinical practice guideline focused update. Arch Pathol Lab Med. 2018;142(11):1364-1382.
2. Allison KH, Hammond MEH, Dowsett M, et al. Estrogen and progesterone receptor testing in breast cancer: ASCO/CAP guideline update. Arch Pathol Lab Med doi: 10.5858/arpa.2019-0904-SA.
3. Dowsett M, Nielsen TO, A'Hern R, et al. Assessment of Ki67 in breast cancer: recommendations from the International Ki67 in breast cancer working group. J Natl Cancer Inst. 2011;103(22):1656-1664.

Reviewed By



Dr. Gulshan Yadav, MD

Head, Pathology

MolQ Laboratory (A Unit of Molecular Quest Healthcare Pvt. Ltd.)

Reference Laboratory:28-29,Sector-18(P) | Gurgaon, Haryana, 122015 | Phone0124 - 4307906, Fax 0124 - 4278596 | Email:contact@molq.in

