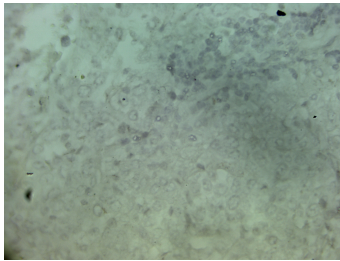


Booking Date: 27/11/2023 Patient ID: 012311270161 Sample Date: 27/11/2023 Name: Ms. SABNAM
Age: 34 years Sex: F Barcode: 11848846

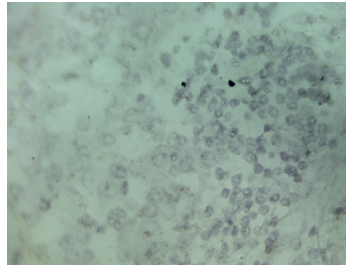
Immunohistochemistry No :- MOLQ IHC- 019-23

Specimen Details: IHC done on blocks no. H- 212/23 E

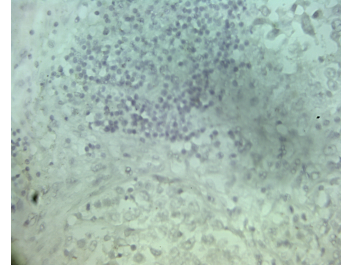
Microscopic Findings:



ER



PR



HER-2

ER PR HER-2/neu

Estrogen Receptor α (ER)

- % Cells immunoreactive – 00%
- Intensity- No staining
- Internal control-Positive
- Interpretation- Negative

Progesterone Receptor (PR)

- % Cells immunoreactive – 00%
- Intensity- No staining
- Internal control-Positive
- Interpretation- Negative

Her-2/neu

- % Cells immunoreactive – 00%
- Intensity- No staining
- Internal control- Positive
- Interpretation- Negative

Results

1. Estrogen Receptor α- **Negative**
2. Progesterone Receptor- **Negative**
3. Her-2/neu- **Negative**