

Booking Date 14/02/2023

Patient ID 012302140306

Sample Date 21/02/2023

Name: Ms. MAJIDAN W/O HANIF

Age: 65 years

Sex: F

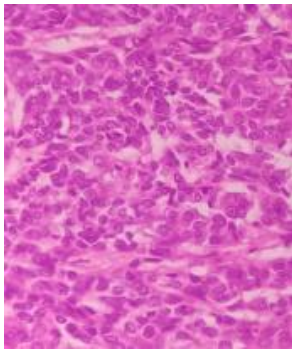
Barcode: 011515217

**Immunohistochemistry No :- MOLQ IHC- 001-23**

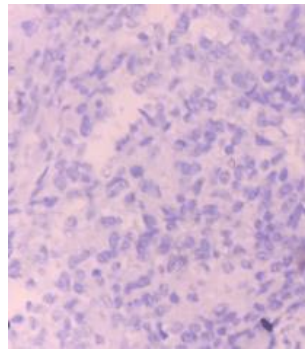
**Clinical Details:** Carcinoma Left breast- Invasive Ductal carcinoma (NST)

**Specimen Details:** IHC done on blocks no. MOLQ B- 217/23 Block F.

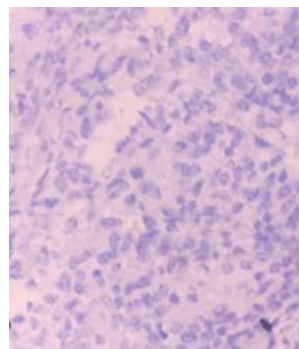
**Microscopic Findings:**



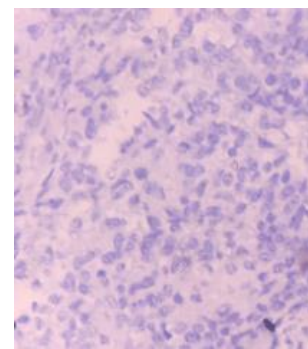
**HPE**



**ER**



**PR**



**HER-2/neu**

**Estrogen Receptor  $\alpha$  (ER)**

- % Cells immunoreactive – 00%
- Intensity- No staining
- Internal control-Positive
- Interpretation- Negative

**Progesterone Receptor (PR)**

- % Cells immunoreactive – 00%
- Intensity- No staining
- Internal control-Positive
- Interpretation- Negative

**Her-2/neu**

- % Cells immunoreactive – 00%
- Intensity- No membranous staining
- Interpretation- Negative

**Results**

1. Estrogen Receptor  $\alpha$ - **Negative**
2. Progesterone Receptor- **Negative**
3. Her-2/neu- **Negative.**