

Booking Date 15/12/2022

Patient ID 012212150242

Sample Date 23/12/2022

Name: Ms. KASHI BAI RAGHUWANSHI

Age: 61 years

Sex: F

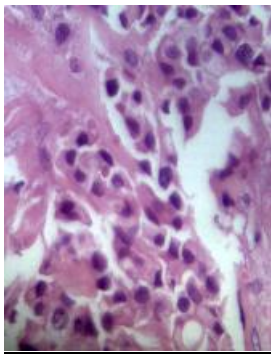
Barcode: 11498528

Immunohistochemistry No :- MOLQ IHC- 005-22

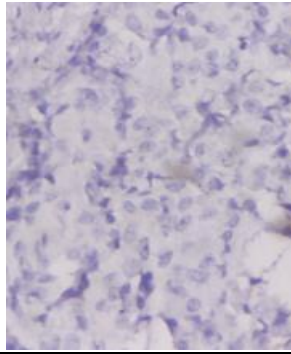
Clinical Details: Carcinoma Right breast- Invasive Ductal carcinoma (NST)

Specimen Details: IHC done on blocks no. MOLQ B- 5818/22

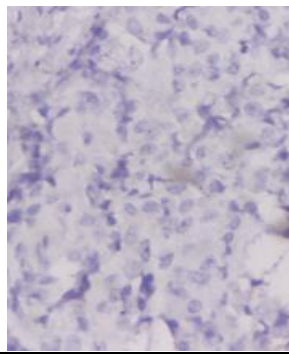
Microscopic Findings:



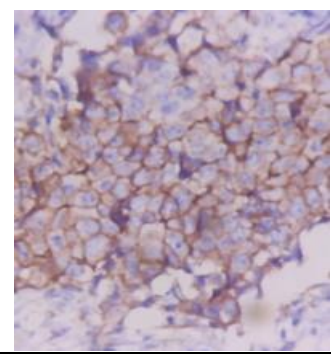
HPE



ER



PR



HER-2/neu

Estrogen Receptor α (ER)

- % Cells immunoreactive – 00%
- Intensity- No staining
- Internal control-Positive
- Interpretation- Negative

Progesterone Receptor (PR)

- % Cells immunoreactive – 00%
- Intensity- No staining
- Internal control-Positive
- Interpretation- Negative

Her-2/neu

- % Cells immunoreactive – 80%
- Intensity- 3+
- Interpretation- Positive

Results

1. Estrogen Receptor α - **Negative**
2. Progesterone Receptor- **Negative**
3. Her-2/neu- **Positive (3+)**