

Booking Date 18/09/2022

Patient ID 012209180155

Sample Date 22/09/2022

Name: Ms. RAMRATI

Age: 68 years

Sex: F

Barcode: 011573481

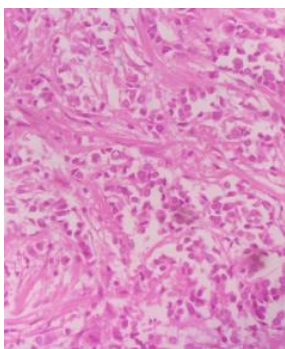
Ref By: Aashtha Path Lab,2

**Immunohistochemistry No :- MOLQ IHC- 002-22**

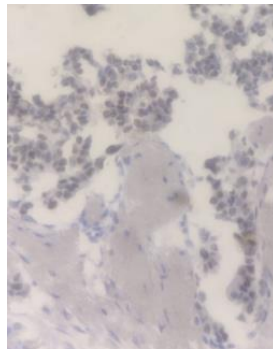
**Clinical Details:** Carcinoma Right breast- Invasive Ductal carcinoma (NST)

**Specimen Details:** IHC done on blocks no. MOLQ B- 4294/22 A6

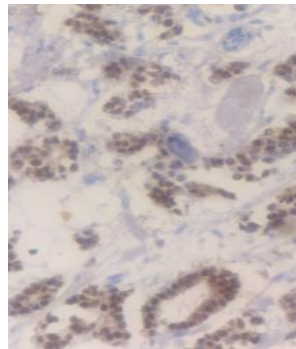
**Microscopic Findings:**



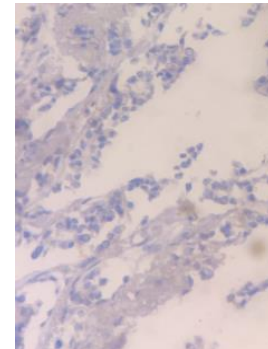
**HPE**



**ER**



**PR**



**HER-2/neu**

**Estrogen Receptor  $\alpha$  (ER)**

- % Cells immunoreactive – 50%
- Intensity- Moderate
- Internal control-Positive
- Interpretation-Positive

**Progesterone Receptor (PR)**

- % Cells immunoreactive – 65%
- Intensity- Strong
- Internal control-Positive
- Interpretation-Positive

**Her-2/neu**

- Total Score- 0
- Interpretation- Negative

**Results**

1. Estrogen Receptor  $\alpha$ - **Positive**
2. Progesterone Receptor- **Positive**
3. Her-2/neu- **Negative**