

Cytomegalovirus (CMV) Immunohistochemistry

Test Description

Cytomegalovirus (CMV), a member of the herpesviridae family, is a double-stranded DNA virus that replicates in the host's nucleus and manifests histopathologically as large intranuclear and smaller cytoplasmic inclusion bodies. It is estimated that CMV colitis occurs in 2-16% of patients who have received solid organ transplants, 3-5% of patients with HIV infection or acquired immunodeficiency syndrome (AIDS), and 4-16% in patients with inflammatory bowel disease (IBD). Diagnosis of CMV infection/reactivation in biopsied tissues is classically based on histopathological identification of virus-infected cells (viral cytopathic effect) on hematoxylin-eosin (H&E) stained slides, and/or detection of CMV intranuclear inclusions by immunohistochemistry (IHC) studies.

Specimen

Sample Type: FFPE block MOLQ B-4086/22
Site: Colonic biopsy
Pathology ID: MOLQ/B- /22
Disease: Chronic Colitis

Interpretation

Positive: Strong, brown, granular intranuclear inclusion bodies staining.

Negative: Absence of strong staining.

Methodology

Immunostaining for CMV stain.

Note

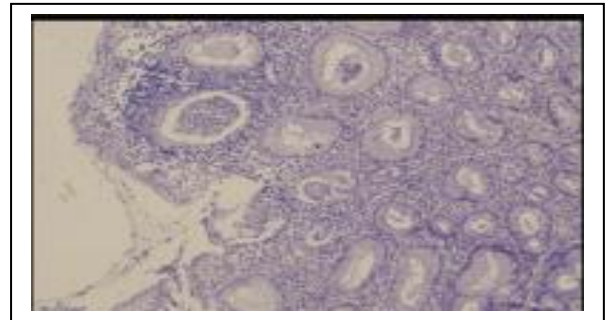
All immunohistochemistry markers have been evaluated in the context of appropriate positive and negative controls. A result is considered uninterpretable as a result of the type of fixative used (non 10% neutral buffered formalin), time to fixation (> 1 hour), duration of fixation (> 6 hr or < 72 hour), strong decalcification, or inappropriate staining of normal internal or external assay controls. An alternative sample for retesting is then usually recommended. These assays have not been validated on decalcified specimens.

References

1. Rosai and Ackerman's Surgical Pathology.

Cytomegalovirus: Negative

CMV IHC



Microscopy Evaluation

CMV staining for tumor cells: **NEGATIVE**

Reviewed By



Dr. Gulshan Yadav,
MDHead, Pathology



CMV-IHC

PATIENT	REPORT DATE	BOOKING ID
AJMER MARTIN	08/09/2022	012209080131