

Booking Date 21/06/2022

Patient ID 102206030022

Sample Date 22/06/2022

Name: Ms. PREMI DEVI

Age: 71 years

Sex: F

Barcode: 11371158

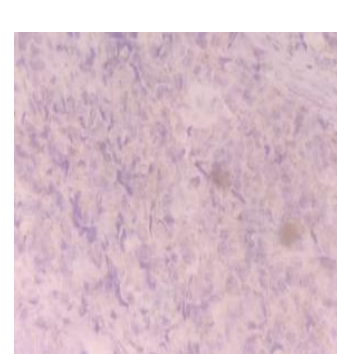
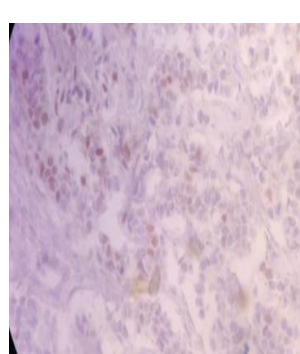
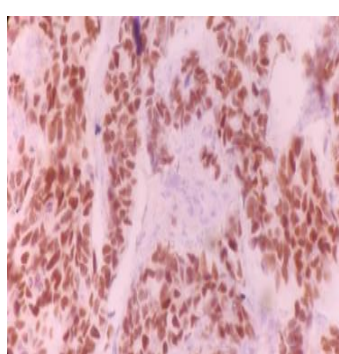
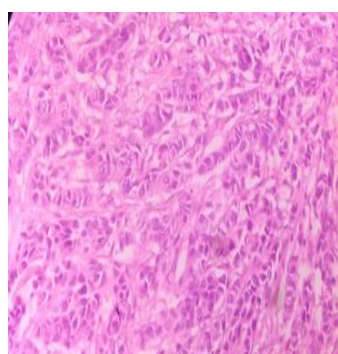
Ref By: S. M. Diagnostics, Kaithal

Immunohistochemistry No :- MOLQ B- 2867-22

Clinical Details: Carcinoma Left breast

Specimen Details: IHC done on blocks no. MOLQ B-1383/22 H

Microscopic Findings:



HPE

ER

PR

HER-2/neu

Estrogen Receptor α (ER)

- % Cells immunoreactive – 80%
- Intensity- Strong
- Internal control-Positive
- Interpretation-Positive

Progesterone Receptor (PR)

- % Cells immunoreactive – 15%
- Intensity- Weak
- Internal control-Positive
- Interpretation-Positive

Her-2/neu

- Total Score- 0
- Interpretation- Negative

Results

1. Estrogen Receptor α - **Positive**
2. Progesterone Receptor- **Positive (Weak)**
3. Her-2/neu- **Negative**