

Programmed Death Ligand 1 (PD-L1) Immunohistochemistry

Test Description

This test is useful for identification of neoplasms expressing programmed cell death 1-ligand 1 (clone SP263). PD-L1 also known as B7 homolog 1 (B7-H1) or CD274, is a transmembrane protein involved in the regulation of cell-mediated immune responses through interaction with the receptor programmed death protein-1 (PD-1). PD-L1 has been identified as both a prognostic and theranostic marker in a variety of neoplasms. Overexpression of PD-L1 has been observed in carcinomas of the urinary bladder, lung, thymus, colon, pancreas, ovary, breast, kidney, and in melanoma and glioblastoma.

Specimen

Sample Type: FFPE cell block C/1169/22
Site: Lung (Cell Block)
Pathology ID: MOLQ/B 2501/22
Disease: Adenocarcinoma

Interpretation

The scoring system is based on type and origin of tumor. If additional interpretation or analysis is needed, send request for Pathology Consultation.

Methodology

Immunostaining for PD-L1 protein was done using Ventana Rabbit Anti-Human PD-L1/CD274 Monoclonal Antibody (Clone SP-263) on Ventana Autostainer. Positive PD-L1 staining/expression is defined as complete and/or partial, circumferential or linear plasma membrane or cytoplasmic staining at any intensity that can be differentiated from background.

Note

Preclinical studies suggest that positive programmed cell death 1-ligand 1 (PD-L1) immunohistochemistry in tumor cells may predict tumor response to therapy with immune checkpoint inhibitors. This result should not be used as the sole factor in determining treatment, as other factors (eg, tumor mutation burden and microsatellite instability) have also been studied as predictive markers.

References

1. Rosai and Ackerman's Surgical Pathology.
2. Modern Surgical Pathology.
3. PD-L1 and gastric cancer prognosis: A systematic review and meta-analysis. Lihu Gu, Manman Chen, Dongyu Guo, Hepan Zhu, Wenchao Zhang. PLOS ONE August 2017
4. Immune Profiling of Adenoid Cystic Carcinoma: PD-L2 Expression and Associations with Tumor-Infiltrating Lymphocytes Vishwajith Sridharan et al. Cancer Immunology Research 2016

Microscopy Evaluation

HE Staining (Figure 1)

Tumor cells: Not applicable on cell block
Immune cells: Not applicable on cell block

Tumor cells positive for PD-L1: 00% (No immunostaining)

Immune cells positive for PD-L1: Not seen in the cell block

HE Stained Section

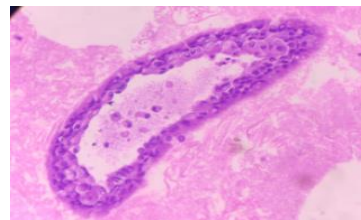


Figure 1

PD-L1 IHC- Tumor Cells



Figure 2

PD-L1 Immunostaining- NEGATIVE

Reviewed By



Dr. Gulshan Yadav, MD
Head, Pathology

MolQ Laboratory (A Unit of Molecular Quest Healthcare Pvt. Ltd.)