



**Dr. Mamta's  
NEULIFE DIAGNOSTICS**

**Dr. Mamta Choudhary**  
MBBS, DNB  
Fetal Medicine  
Fetal Imaging Specialist

**Patient Details: Mrs. Sukhman / 37 Years / Female**

**Reference by Dr. Sunita Choudhary Date: Thursday, September 09, 2021**

**FETAL ULTRASONOGRAPHY SCAN REPORT: TARGETED SCAN**

*(Equipment used is GE- Voluson S8 with convex 4CD high density probe)*

Single live intrauterine pregnancy seen in Breech Presentation at present.

Amniotic fluid: Adequate

Fetal movements and Cardiac activity: Present (FHR: 153 beats / min).

Placental position: Posterior low lying lower end distance from internal os 25 mm, Grade I.

Umbilical cord shows 3vessels with normal placental and fetal abdominal insertions.

Internal os is closed. Cervical length (34mm) is normal.

**Biometry:**

Bi Parietal Diameter(BPD)	43mm	19 weeks	1days
Head Circumference (HC)	157mm	18 weeks	4 days
Abdominal Circumference(AC)	117mm	19weeks	1 days
Humerus Length(HL)	26mm	18 weeks	3 days
Radius Length(RL)	25mm	18weeks	6 days
Femur Length (FL)	29mm	19weeks	1days
Fibular Length (Fib)	26 mm	18weeks	0days
Tibia Length(TL)	26 mm	18 weeks	5 days
Trans Cerebellar Diameter(TCD)	17mm	18weeks	3days
Bi Orbital Diameter(BOD)	27mm	18weeks	0days
Estimated Fetal weight	274 +/- 40gms		
Nuchal Fold Thickness(NF)	2.4 mm		
Cisterna magna (CM)	3.1mm		
Nasal bone(NB)	7.2mm		
Maximum lateral ventricle diameter(VSP)	6.8mm		

Dr. Mamta's Neulife Diagnostics Pvt. Ltd. is a registered company under the Companies Act, 2013. The company is engaged in the business of providing diagnostic services. The company is a part of the Dr. Mamta's Neulife Diagnostics Group of Companies. The company is a part of the Dr. Mamta's Neulife Diagnostics Group of Companies. The company is a part of the Dr. Mamta's Neulife Diagnostics Group of Companies.

*Handwritten signature and date: 09/09/2021*





# Dr. Mamta's NEULIFE DIAGNOSTICS

1. Jyoti Choudhary, MBBS, DMRD  
2. Dr. Mamta Dhaka, MBBS, DMRD

## Colour and spectral Doppler- qualitative and quantitative study:

Bilateral uterine arteries show normal RI, PI, PSV and spectral waveform patterns of the flow.

	PI	RI	SD Ratio
Rt. Uterine A.	0.61	0.45	1.8
Lt. Uterine A.	0.80	0.52	1.8


## IMPRESSION:

Single Live intrauterine pregnancy of size 19 weeks with Breech Presentation at present.

Detailed scan for search of congenital anomalies shows no obvious abnormality

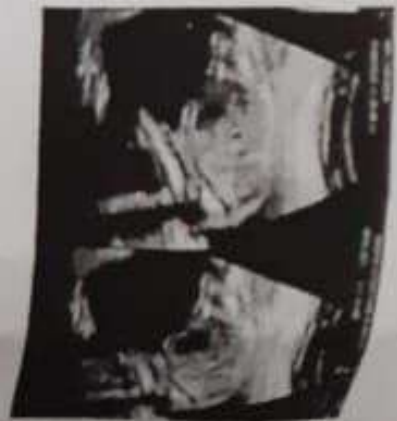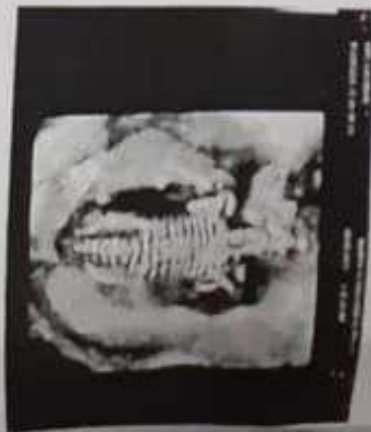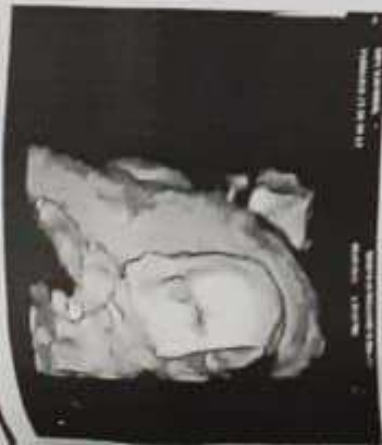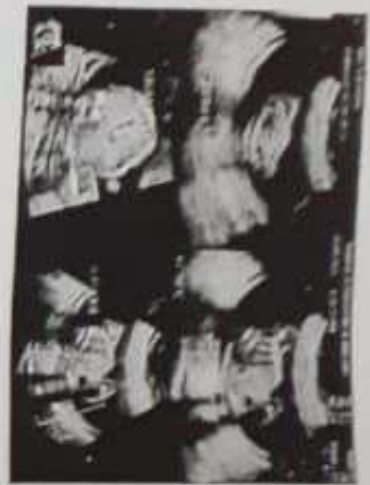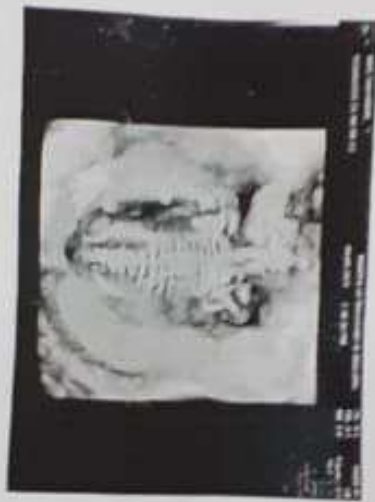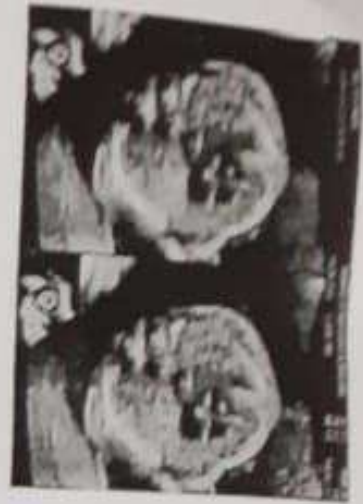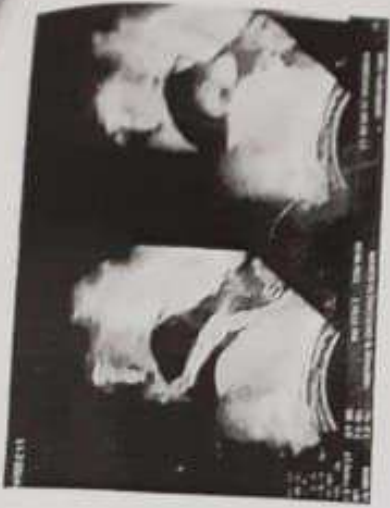"While conducting ultrasound scan, I have not disclosed the sex of fetus to anybody in any manner."

**Note:** Not all congenital anomaly specially of the heart, limbs and chromosomal abnormalities can be ruled out on an ultrasound.

  
Dr. Mamta Dhaka  
Consultant Radiologist  
Dr. Mamta Dhaka  
MBBS, DMRD  
Consultant Radiologist  
Reg. No. 28545/11/2019

इण्टिग्रेटेड परीक्षण की शिकायत 104 पर निःशुल्क दर्ज की जा सकती है।

(Unit of Mamta Ultrasound & Imaging)  
51, Parasram Nagar, Dehar Ke Balaji, Sikar Road, Jaipur - 302039  
Appointments: +91 92510 01110 • E-mail: neulifehealthcare@gmail.com



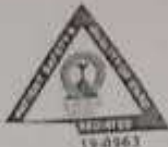CHIEF MEDICAL & HEALTH OFFICER JAIPUR-1.





# Dana Shivam HEART & SUPER SPECIALITY HOSPITAL

SPRIT TO CARE. SKILL TO HEAL



- CARDIOLOGY**  
Dr. Sandeep Kumar Garssa  
Director  
Dr. Shalini Tomar Garssa  
Dr. Divy Khetan  
Dr. Jyoti Bugala
- CARDIAC SURGERY**  
Dr. Vinod Gupta
- NEUROSURGERY**  
Dr. Rajiv Singh Garssa
- GASTROENTEROLOGY**  
Dr. Subhash Doot
- MEDICINE**  
Dr. C.P. Suthar
- UROLOGY**  
Dr. Sanjay Goyal
- GENERAL SURGERY**  
Dr. Kamlesh Agarwal
- VASCULAR SURGERY**  
Dr. Govind Prasad Dubey
- ORTHOPAEDIC**  
Dr. Nitin Gupta
- GYNACOLOGY & OBSTETRICS**  
Dr. Sumita Choudhary
- PLASTIC SURGERY**  
Dr. Vipin Barala  
Dr. Shanu Agarwal
- PEDIATRICS**  
Dr. Anil Kumar Khechar
- ENT**  
Dr. B.K. Chhabra
- RADIOLOGY**  
Dr. Himanshu Agarwal
- PHYSIOTHERAPY**  
Dr. Bharat Gupta

Reg No: 0058218 / J  
 Date: 09/09/2023 10:50:23 AM  
 Name: SUKHAMAN KANWAR  
 Age/Gender: 72 / M  
 Dr: SUMITA CHOUDHARY

Pulse: \_\_\_\_\_ Height: \_\_\_\_\_ Temp: \_\_\_\_\_  
 BP: 100/70 mmHg Weight: 71 kg Allergy: \_\_\_\_\_

**Rx**  
 Provisional Diagnosis: G6P2L1A3 w/ 16+6 wk. 65.4  
 18-15 wk (By USG)

Significant Examination & Investigation	Medicine	Strength	Dose Instruction	Duration
ADW - Vst (obst) Lesel II Syncope marker			EOS - 2/1/2/2/2	
			DA - Vt. 16 wk FTS + 140/min R	
			ADW - Rest in Ltz lateral position. Tab Escorpin 75 mg	
			Tab. Curral-X 100	
			Cap. Snoten 500mg	
			Tab. Rimadon 100	

SL of 15 wks  
 Bveth presentation  
 11 - poor low lying 26mm -  
 10mm antenatal  
 Key edel  
 Echogenic seen in  
 joints scan in  
 left ventricle by

Follow up at \_\_\_\_\_  
 With Reports \_\_\_\_\_  
 Past/Present History \_\_\_\_\_

In Case of Appointment Dial: 911 600 3461  
 In Case of Emergency Dial: 911 600 3470

SOS Dispensary

**PAIN SCALE**

गुणवत् इलाज की सलाह के बिना दवाईयें लेना बंद ना करें।

A Unit of PRANSS HEALTHCARE INDIA PVT. LTD.  
 2, Sector-2, Central Spine, Vidyadhar Nagar, Jaipur-302023 (Rajasthan) INDIA  
 Tel.: 0141-223-2220, 911 600 3461 | E-mail: shivamhearthospital@gmail.com | Web: www.danashivamhospital.com  
 2, Sector-2, Central Spine, Vidyadhar Nagar, Jaipur-302023 (Rajasthan) INDIA  
 Tel.: 0141-223-2220, 911 600 3461 | E-mail: shivamhearthospital@gmail.com | Web: www.danashivamhospital.com

4- 5.4  
 10- 72 kg