

**Patient Name** Mrs. RANJANA  
**Age/Sex** 27YRS/F  
**Patient ID** 012003150255  
**Specimen ID** MOLQ/B-650-20

**Client Name** Goyal Nursing Home,  
Palwal

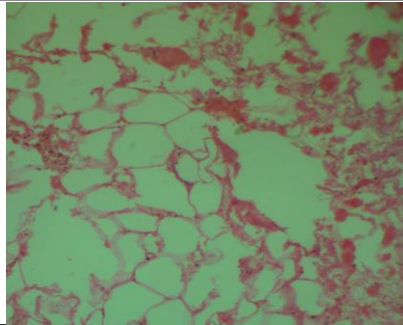
**Specimen Received** 15-03-2020  
**Specimen Type** Tissue  
**Collection Date** 15-03-2020  
**Report Date** 19-03-2020

## SURGICAL PATHOLOGY REPORT

### Swelling Right Axilla

#### DIAGNOSIS

#### EPIDERMAL CYST



#### SPECIMEN

Swelling Right Axilla

#### GROSS

Received 9x6 cm fatty tissue with skin attached.

#### Microscopy

Section examined shows squamous lining epithelium with round to oval nuclei with keratinosis and parakeratosis. Deeper tissue shows fibrocollagenous tissue, blood vessels and mature adipose cells. No granuloma seen. No malignant cells seen.

**Note :** All biopsy specimen will be stored for 15 (fifteen) days, block and slides for 5 (five) years only from the time of receipt at the laboratory. No request, for any of the above, will be entertained after the due date.

#### Reference

- i) Rosai and Ackerman's Surgical Pathology.
- ii) Modern Surgical Pathology.



**Gulshan Yadav, MD**  
Consultant Pathologist