

Patient Name Ms. SANZIDA
Age/Sex 37YRS/F
Patient ID 012003140170
Specimen ID MOLQ/B-634-20

Client Name Family Hospital and
Surgical Centre

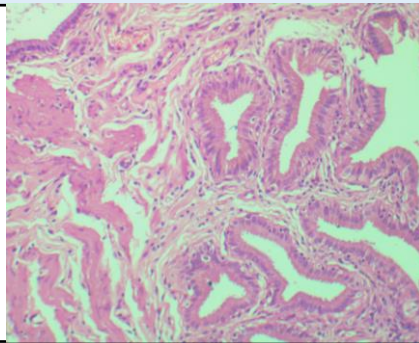
Specimen Received 14-03-2020
Specimen Type Tissue
Collection Date 14-03-2020
Report Date 17-03-2020

SURGICAL PATHOLOGY REPORT

Gall Bladder

DIAGNOSIS

CHOLECYSTITIS AND CHOLELITHIASIS.



SPECIMEN

Gall Bladder

GROSS

Received autolyzed 10x4cm long gall bladder. Cut section shows stones. Wall Thickness 0.2 mm.

Microscopy

Section examined shows autolytic changes with ulcerative mucosa and Rokitansky-Aschoff sinus (irregularly shaped tubular structures lined by cuboidal lining epithelium with round to oval nucleus) with fibro collagenous tissue and inflammatory cells (lymphocytes).

Note : All biopsy specimen will be stored for 15 (fifteen) days, block and slides for 5 (five) years only from the time of receipt at the laboratory. No request, for any of the above, will be entertained after the due date.

Reference

- i) Rosai and Ackerman's Surgical Pathology.
- ii) Modern Surgical Pathology.

A handwritten signature in black ink, appearing to read 'Gulshan', written over a light blue rectangular background.

Gulshan Yadav, MD
Consultant Pathologist