

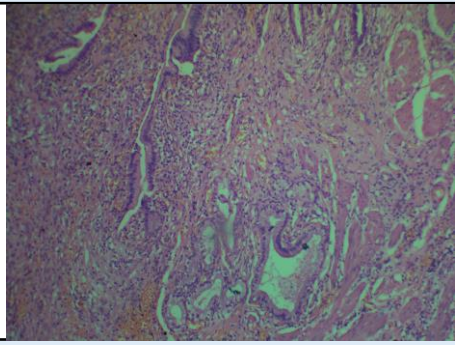
Patient Name	Ms. SARA BANO R/O D K MARG	Client Name	Apex Medicare, Jammu & Kashmir	Specimen Received	11-Feb-2020
Age/Sex	50 YRS/F			Specimen Type	Tissue
Patient ID	042003110183			Collection Date	11-Feb-2020
Specimen ID	MOLQ/B-599/2020			Report Date	16-Feb-2020

SURGICAL PATHOLOGY REPORT

Gall Bladder

IMPRESSION **DIAGNOSIS**

CHOLECYSTITIS AND CHOLELITHIASIS.



SPECIMEN
Gall Bladder

GROSS
Received 9x3cm long gall bladder already cut open with tiny stones. wall thickness 0.4mm.


Microscopy

Section examined shows ulcerative mucosa and rokitansky aschoff sinus (irregularly shaped tubular structures lined by cuboidal lining epithelium with round to oval nucleus) with fibro collagenous tissue and inflammatory cells (lymphocytes).

Note : All biopsy specimen will be stored for 15 (fifteen)days, block and slides for 5(five) years only from the time of receipt at the laboratory. No request ,for any of the above ,will be entertained after the due date.

Reference

- i) Rosai and Ackerman's Surgical Pathology.
- ii) Modern Surgical Pathology.


Gulshan Yadav, MD
Consultant Pathologist