

Patient Name Ms. JAMEELA BANO R/O BIDDAR
Age/Sex 45 YRS/F
Patient ID 042003110182
Specimen ID MOLQ/B-606-20

Client Name Apex Medicare, Jammu
& Kashmir

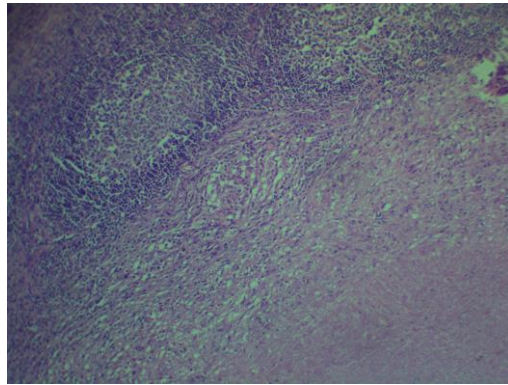
Specimen Received 11-03-2020
Specimen Type Tissue
Collection Date 11-03-2020
Report Date 16-03-2020

SURGICAL PATHOLOGY REPORT

Left Groin

DIAGNOSIS

NECROTIZING LYMPHADENITIS
(TUBERCULAR PATHOLOGY STRONGLY SUSPICIOUS).



SPECIMEN

Left Groin

GROSS

Received 9x6 cm grayish yellowish tissue piece with skin attached.

Microscopy


Section examined shows lymphoid follicles with surrounding tissue. Section shows areas of caseous necrosis surrounded by histiocytes / epithelioid cells.

No malignant cells seen.

Note : All biopsy specimen will be stored for 15 (fifteen) days, block and slides for 5 (five) years only from the time of receipt at the laboratory. No request, for any of the above, will be entertained after the due date.

Reference

- i) Rosai and Ackerman's Surgical Pathology.
- ii) Modern Surgical Pathology.



Gulshan Yadav, MD
Consultant Pathologist