

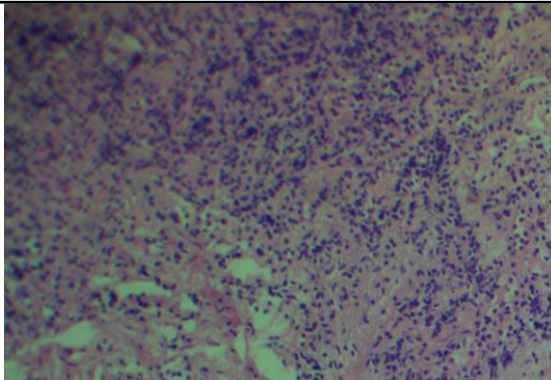
Patient Name	Mrs. SHEELA 59439	Client Name	S. M. Diagnostics, Kaithal	Specimen Received	09/03/2020
Age/Sex	32YRS/F			Specimen Type	Tissue
Patient ID	102003090031			Collection Date	09/03/2020
Specimen ID	MOLQ/B-582-20			Report Date	13/03/2020

SURGICAL PATHOLOGY REPORT

Appendix

DIAGNOSIS

ACUTE APPENDICITIS



SPECIMEN

Appendix

GROSS

Received 5x2 cm long appendix. Cut section shows fecolith.

Microscopy

Section examined shows lymphoid follicles with ulcerative mucosa. Deeper tissue shows inflammatory cells (polymorphs and lymphocytes). No granuloma seen. No malignant cells seen.

Note : All biopsy specimen will be stored for 15 (fifteen) days, block and slides for 5 (five) years only from the time of receipt at the laboratory. No request, for any of the above, will be entertained after the due date.

Reference

- i) Rosai and Ackerman's Surgical Pathology.
- ii) Modern Surgical Pathology.

Gulshan Yadav, MD
Consultant Pathologist