

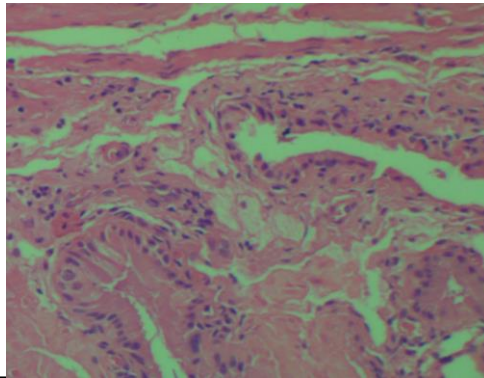
Patient Name	Ms. IFSHANA/PANZOO	Client Name	Walk-in	Specimen Received	09/03/2020
Age/Sex	16YRS/F			Specimen Type	Tissue
Patient ID	042003090188			Collection Date	09/03/2020
Specimen ID	MOLQ/B-592-20			Report Date	13/03/2020

SURGICAL PATHOLOGY REPORT

Gall Bladder

DIAGNOSIS

CHOLECYSTITIS.



SPECIMEN

Gall Bladder

GROSS

Received 6x2.5 cm long gall bladder. Cut section shows no stones. Wall thickness 0.3 mm.


Microscopy

Section examined shows ulcerative mucosa and Rokitansky-Aschoff sinus (irregularly shaped tubular structures lined by cuboidal lining epithelium with round to oval nucleus) with fibrocollagenous tissue and inflammatory cells (lymphocytes).

Note : All biopsy specimen will be stored for 15 (fifteen) days, block and slides for 5 (five) years only from the time of receipt at the laboratory. No request, for any of the above, will be entertained after the due date.

Reference

- i) Rosai and Ackerman's Surgical Pathology.
- ii) Modern Surgical Pathology.


Gulshan Yadav, MD
Consultant Pathologist