

Patient Name Mrs. VINTI
Age/Sex 26YRS/F
Patient ID 092003070014
Specimen ID MOLQ/B-561/2020

Client Name Civil Hospital Sec-10

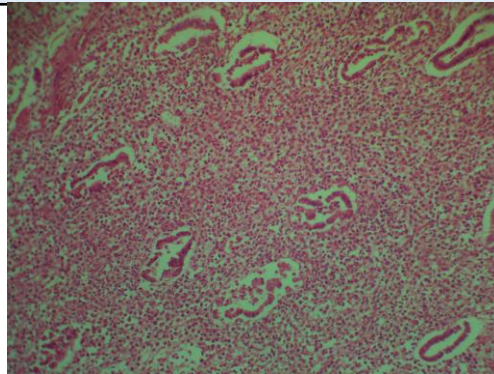
Specimen Received 07/03/2020
Specimen Type Tissue
Collection Date 07/03/2020
Report Date 12/03/2020

SURGICAL PATHOLOGY REPORT

Endometrial biopsy

DIAGNOSIS

PROLIFERATIVE PHASE



SPECIMEN

Endometrial biopsy

GROSS

Received multiple grayish white tissue piece.

Microscopy


Section examined shows small endometrial glands with columnar lining with small round to oval nucleus. Stroma shows mononuclear inflammatory cells and RBCs.

No granuloma seen. No malignant cells seen.

Note : All biopsy specimen will be stored for 15 (fifteen)days, block and slides for 5(five) years only from the time of receipt at the laboratory. No request ,for any of the above ,will be entertained after the due date.

Reference

- i) Rosai and Ackerman's Surgical Pathology.
- ii) Modern Surgical Pathology.


Gulshan Yadav, MD
Consultant Pathologist