

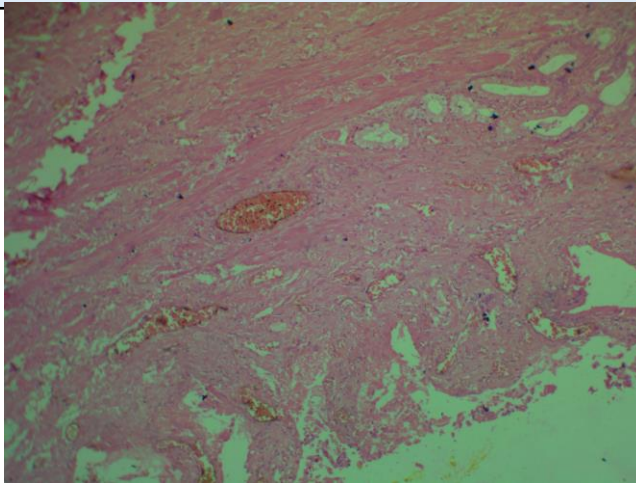
<b>Patient Name</b>	Ms. HAJIRA R/O CHIMMAR	<b>Client Name</b>	Apex Medicare, Jammu & Kashmir	<b>Specimen Received</b>	09/03/2020
<b>Age/Sex</b>	56YRS/F			<b>Specimen Type</b>	Tissue
<b>Patient ID</b>	042003070077			<b>Collection Date</b>	09/03/2020
<b>Specimen ID</b>	MOLQ/B-588-20			<b>Report Date</b>	12/03/2020

## SURGICAL PATHOLOGY REPORT

### Gall Bladder

#### DIAGNOSIS

CHOLECYSTITIS.



#### SPECIMEN

Gall Bladder

#### GROSS

Received 7x3.5 cm long gall bladder. Cut section shows no stones. Wall thickness 0.3 mm.

#### Microscopy

Section examined shows ulcerative mucosa and Rokitansky-Aschoff sinuses (irregularly shaped tubular structures lined by cuboidal lining epithelium with round to oval nucleus) with fibrocollagenous tissue and inflammatory cells (lymphocytes).

**Note :** All biopsy specimen will be stored for 15 (fifteen) days, block and slides for 5 (five) years only from the time of receipt at the laboratory. No request, for any of the above, will be entertained after the due date.

#### Reference

- i) Rosai and Ackerman's Surgical Pathology.
- ii) Modern Surgical Pathology.

**Gulshan Yadav, MD**  
Consultant Pathologist