

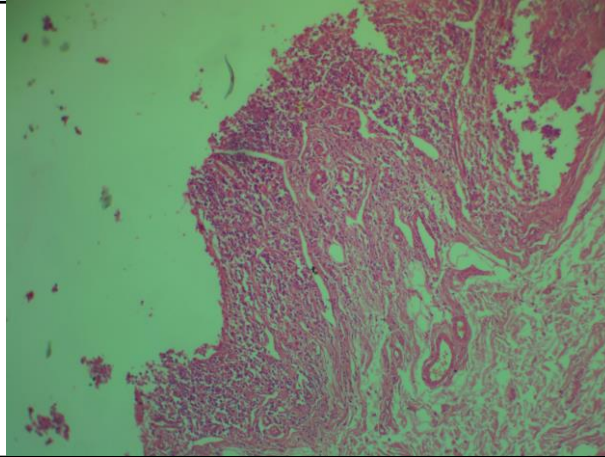
|                     |                                |                    |                                   |                          |            |
|---------------------|--------------------------------|--------------------|-----------------------------------|--------------------------|------------|
| <b>Patient Name</b> | Mr. AATIF AHMAD R/O<br>DEV SAR | <b>Client Name</b> | Apex Medicare, Jammu &<br>Kashmir | <b>Specimen Received</b> | 08/03/2020 |
| <b>Age/Sex</b>      | 15YRS/M                        |                    |                                   | <b>Specimen Type</b>     | Tissue     |
| <b>Patient ID</b>   | 042003060024                   |                    |                                   | <b>Collection Date</b>   | 08/03/2020 |
| <b>Specimen ID</b>  | MOLQ/B-575-20                  |                    |                                   | <b>Report Date</b>       | 12/03/2020 |

## SURGICAL PATHOLOGY REPORT

### Appendix

#### DIAGNOSIS

ACUTE APPENDICITIS



#### SPECIMEN

Appendix

#### GROSS

Received 7x2 cm long appendix. Cut section shows fecolith.

#### Microscopy

Section examined shows lymphoid follicles with ulcerative mucosa. Deeper tissue shows inflammatory cells (polymorphs and lymphocytes). No granuloma seen. No malignant cells seen.

**Note :** All biopsy specimen will be stored for 15 (fifteen) days, block and slides for 5 (five) years only from the time of receipt at the laboratory. No request, for any of the above, will be entertained after the due date.

#### Reference

- i) Rosai and Ackerman's Surgical Pathology.
- ii) Modern Surgical Pathology.

**Gulshan Yadav, MD**  
Consultant Pathologist