

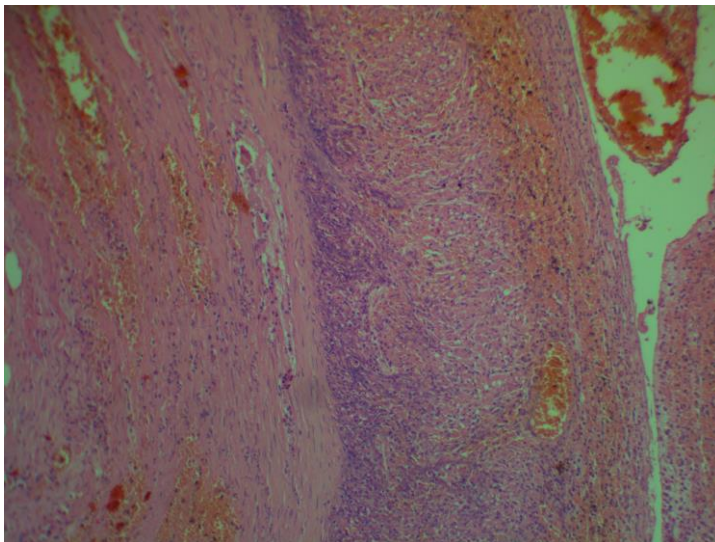
Patient Name	Mr. DHEERAJ	Client Name	Goyal Nursing Home, Palwal	Specimen Received	08/03/2020
Age/Sex	28YRS/M			Specimen Type	Tissue
Patient ID	012003080201			Collection Date	08/03/2020
Specimen ID	MOLQ/B-572-20			Report Date	12/03/2020

SURGICAL PATHOLOGY REPORT

Appendix

DIAGNOSIS

ACUTE APPENDICITIS



SPECIMEN

Appendix

GROSS

Received 7X2 cm long appendix. Cut section shows fecolith.

Microscopy

Section examined shows lymphoid follicles with ulcerative mucosa. Deeper tissue shows inflammatory cells (polymorphs and lymphocytes). No granuloma seen. No malignant cells seen.

Note : All biopsy specimen will be stored for 15 (fifteen) days, block and slides for 5 (five) years only from the time of receipt at the laboratory. No request, for any of the above, will be entertained after the due date.

Reference

- i) Rosai and Ackerman's Surgical Pathology.
- ii) Modern Surgical Pathology.

Gulshan Yadav, MD
Consultant Pathologist