

Patient Name Mrs. KANIKA
Age/Sex 25YRS/F
Patient ID 012003070170
Specimen ID MOLQ/B-565-20

Client Name Dr Heart Path Lab C/o
Navjeevan Hospital & Maternity Center

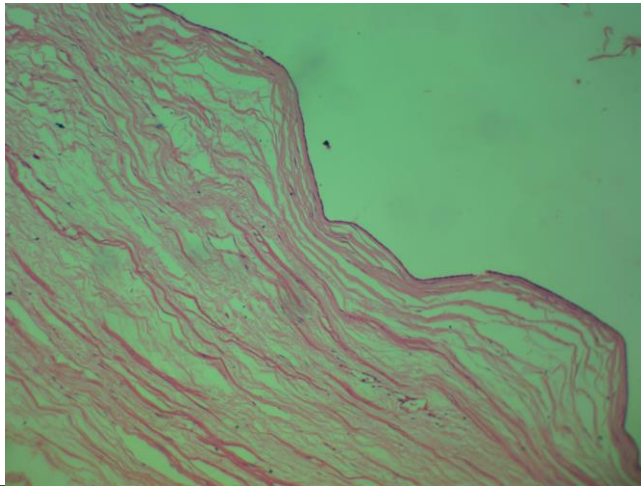
Specimen Received 07/03/2020
Specimen Type Tissue
Collection Date 07/03/2020
Report Date 12/03/2020

SURGICAL PATHOLOGY REPORT

Perifimbrial Cyst

DIAGNOSIS

PARATUBAL CYST
CONSENSUS WITH CLINICAL FINDINGS.



SPECIMEN

Perifimbrial Cyst

GROSS

Received 10x6 cm cystic tissue piece. Cut section shows brown colored fluid.

Microscopy

Section examined shows cuboidal cystic lining epithelium with round to oval nucleus with flat interface. Deeper tissue shows fibrocollagenous tissue and blood vessels.
No granuloma seen. No malignant cells seen.

Note : All biopsy specimen will be stored for 15 (fifteen) days, block and slides for 5 (five) years only from the time of receipt at the laboratory. No request ,for any of the above ,will be entertained after the due date.

Reference

- i) Rosai and Ackerman's Surgical Pathology.
- ii) Modern Surgical Pathology.

Gulshan Yadav, MD
Consultant Pathologist