

Patient Name Ms. SARITA
Age/Sex 22YRS/F
Patient ID 012003070028
Specimen ID MOLQ/B-552/2020

Client Name Star Path Lab, NNL

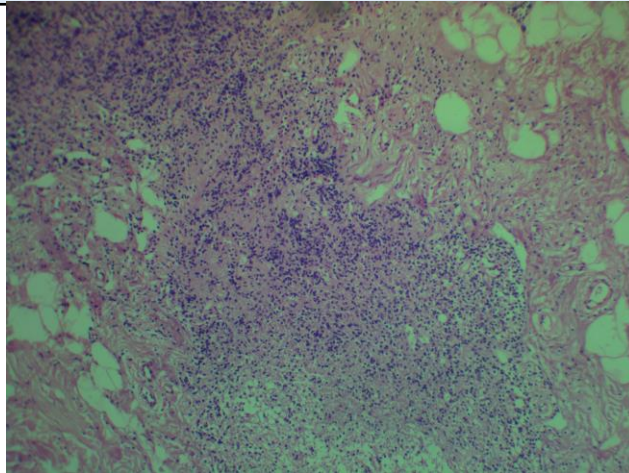
Specimen Received 07/03/2020
Specimen Type Tissue
Collection Date 07/03/2020
Report Date 12/03/2020

SURGICAL PATHOLOGY REPORT

Ruptured Appendix

DIAGNOSIS

ACUTE APPENDICITIS



SPECIMEN

Ruptured Appendix

GROSS

Received autolyzed 6.5x2.2cm long appendix. Cut section shows feco-lith.

Microscopy

Section examined shows autolyzed with lymphoid follicles with ulcerative mucosa. Deeper tissue shows inflammatory cells (polymorphs and lymphocytes). No granuloma seen. No malignant cells seen.

Note : All biopsy specimen will be stored for 15 (fifteen)days, block and slides for 5(five) years only from the time of receipt at the laboratory. No request ,for any of the above ,will be entertained after the due date.

Reference

- i) Rosai and Ackerman's Surgical Pathology.
- ii) Modern Surgical Pathology.



Gulshan Yadav, MD
Consultant Pathologist