

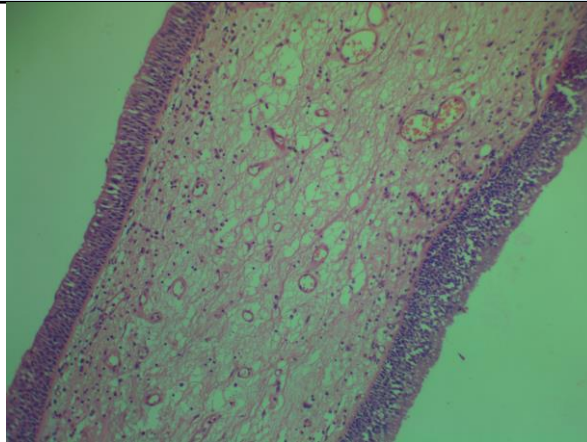
Patient Name	Mr. BHUPENDER 49837	Client Name	Pushpanjali Hospital (Rewari)	Specimen Received	07/03/2020
Age/Sex	28YRS/M			Specimen Type	Tissue
Patient ID	012003070026			Collection Date	07/03/2020
Specimen ID	MOLQ/B-550-20			Report Date	12/03/2020

SURGICAL PATHOLOGY REPORT

Right Nasal Polyp

DIAGNOSIS

INFLAMMATORY POLYP



SPECIMEN

Right Nasal Polyp

GROSS

Received 2x2 cm grayish white tissue piece.

Microscopy

Section examined shows stratified squamous lining epithelium to pseudocolumnar ciliated lining epithelium with flat interface. Deeper tissue shows fibrocollagenous tissue, blood vessels and inflammatory cells (lymphocytes and plasma cells)
No granuloma seen. No malignant cells seen.

Note : All biopsy specimen will be stored for 15 (fifteen)days, block and slides for 5(five) years only from the time of receipt at the laboratory. No request ,for any of the above ,will be entertained after the due date.

Reference

- i) Rosai and Ackerman's Surgical Pathology.
- ii) Modern Surgical Pathology.

Gulshan Yadav, MD
Consultant Pathologist