

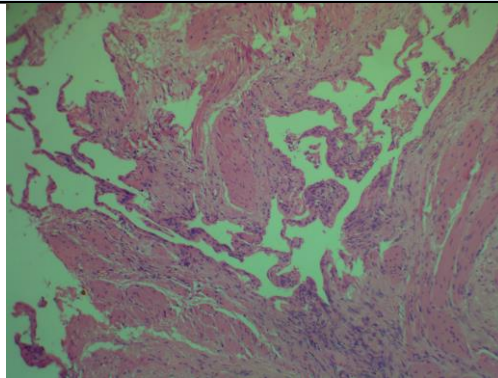
Patient Name	Ms. SANTOSH PANWAR	Client Name	Care Diagnostics Centre	Specimen Received	06/03/2020
Age/Sex	55YRS/F			Specimen Type	Tissue
Patient ID	012003060186			Collection Date	06/03/2020
Specimen ID	MOLQ/B-556-20			Report Date	12/03/2020

SURGICAL PATHOLOGY REPORT

Gall Bladder

DIAGNOSIS

CHOLECYSTITIS AND CHOLELITHIASIS.



SPECIMEN

Gall Bladder

GROSS

Received 6.5x2.1 cm long gall bladder. Cut section shows stones.

Microscopy

Section examined shows ulcerative mucosa and Rokitansky-Aschoff sinuses (irregularly shaped tubular structures lined by cuboidal lining epithelium with round to oval nucleus) with fibrocollagenous tissue and inflammatory cells (lymphocytes).

Note : All biopsy specimen will be stored for 15 (fifteen) days, block and slides for 5 (five) years only from the time of receipt at the laboratory. No request, for any of the above, will be entertained after the due date.

Reference

- i) Rosai and Ackerman's Surgical Pathology.
- ii) Modern Surgical Pathology.

Gulshan Yadav, MD
Consultant Pathologist