

Patient Name Mrs. RAM KALA
Age/Sex 61YRS/F
Patient ID 012003050112
Specimen ID MOLQ/B-543-20

Client Name Lifeaid Wellness Centre

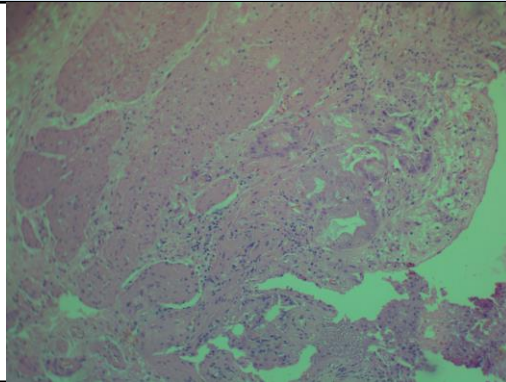
Specimen Received 05/03/2020
Specimen Type Tissue
Collection Date 05/03/2020
Report Date 11/03/2020

SURGICAL PATHOLOGY REPORT

Gall Bladder

DIAGNOSIS

CHOLECYSTITIS.



SPECIMEN

Gall Bladder

GROSS

Received 9X1.9 cm long gall bladder already cut open without stones.


Microscopy

Section examined shows ulcerative mucosa and Rokitansky-Aschoff sinuses (irregularly shaped tubular structures lined by cuboidal lining epithelium with round to oval nucleus) with fibrocollagenous tissue and inflammatory cells (lymphocytes).

Note : All biopsy specimen will be stored for 15 (fifteen) days, block and slides for 5 (five) years only from the time of receipt at the laboratory. No request, for any of the above, will be entertained after the due date.

Reference

- i) Rosai and Ackerman's Surgical Pathology.
- ii) Modern Surgical Pathology.


Gulshan Yadav, MD
Consultant Pathologist