

Patient Name Ms. FEHMEEDA
Age/Sex 30YRS/F
Patient ID 042003040070
Specimen ID MOLQ/B-532-20

Client Name Max Well Health Care
Jammu & Kashmir

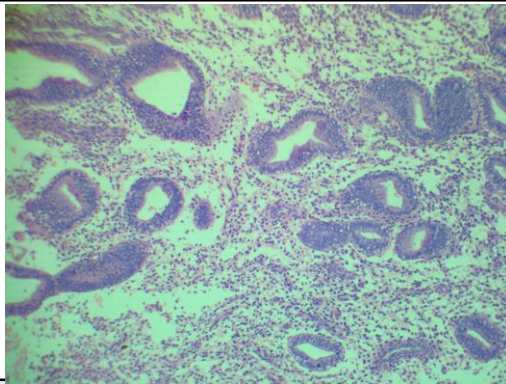
Specimen Received 05/03/2020
Specimen Type Tissue
Collection Date 05/03/2020
Report Date 06/03/2020

SURGICAL PATHOLOGY REPORT

Endometrium Currettings

DIAGNOSIS

DISORDERED PROLIFERATIVE PHASE



SPECIMEN

Endometrium Currettings

GROSS

Received multiple grayish white tissue piece.

Microscopy


Section examined shows small and tortous endometrial glands with cuboidal lining with small round nucleus (few glands shows vacuolization). Stroma shows mononuclear inflammatory cells.

No granuloma seen. No malignant cells seen.

Note : All biopsy specimen will be stored for 15 (fifteen)days, block and slides for 5(five) years only from the time of receipt at the laboratory. No request ,for any of the above ,will be entertained after the due date.

Reference

- i) Rosai and Ackerman's Surgical Pathology.
- ii) Modern Surgical Pathology.


Gulshan Yadav, MD
Consultant Pathologist