

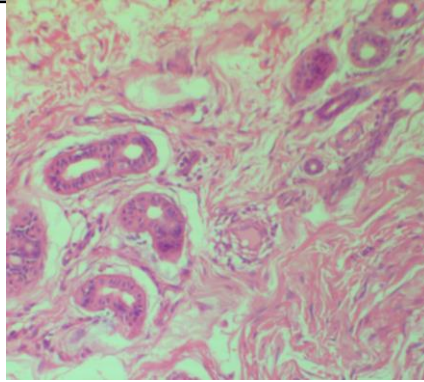
Patient Name	Ms. AMINA 764 HYHAMA	Client Name	Apollo Laboratories CC, Jammu & Kashmir ri)	Specimen Received	01/03/2020
Age/Sex	20YRS/F			Specimen Type	Tissue
Patient ID	042003010075			Collection Date	01/03/2020
Specimen ID	MOLQ/B-510-20			Report Date	04/03/2020

SURGICAL PATHOLOGY REPORT

Swelling Left Breast

DIAGNOSIS

BENIGN BREAST LESION



SPECIMEN

Swelling Left Breast

GROSS

Received 3.2x2.8 cm greyish white tissue piece.

Microscopy

Section examined shows ducts (few cystically dilated) with cuboidal epithelium with small round nucleus

surrounded by fibro collagenous tissue.

No granuloma seen. No malignant cells seen.

Note : All biopsy specimen will be stored for 15 (fifteen)days, block and slides for 5(five) years only from the time of receipt at the laboratory. No request ,for any of the above ,will be entertained after the due date.

Reference

- i) Rosai and Ackerman's Surgical Pathology.
- ii) Modern Surgical Pathology.

Gulshan Yadav, MD
Consultant Pathologist