

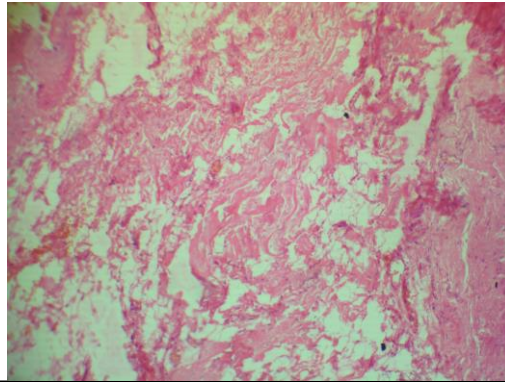
<b>Patient Name</b>	Mrs. NASREENA 746 KANDI	<b>Client Name</b>	Apollo Laboratories CC, Jammu & Kashmir	<b>Specimen Received</b>	29/02/2020
<b>Age/Sex</b>	30YRS/F			<b>Specimen Type</b>	Tissue
<b>Patient ID</b>	042002290074			<b>Collection Date</b>	29/02/2020
<b>Specimen ID</b>	MOLQ/B-502-20			<b>Report Date</b>	04/03/2020

## SURGICAL PATHOLOGY REPORT

### Left Ovarian Cyst

#### DIAGNOSIS

**HEMORRHAGIC CYST**  
**(ENDOMETRIOTIC CYST)**



#### SPECIMEN

Left Ovarian Cyst

#### GROSS

Received 7x8.5 cm cystic tissue piece already cut open.

#### Microscopy

Section examined shows ovarian tissue with large number of RBCs, hemosiderin laden macrophages, ? glands with cuboidal lining epithelium.

No granuloma seen. No malignant cells seen.

**Note :** All biopsy specimen will be stored for 15 (fifteen)days, block and slides for 5(five) years only from the time of receipt at the laboratory. No request ,for any of the above ,will be entertained after the due date.

#### Reference

- i) Rosai and Ackerman's Surgical Pathology.
- ii) Modern Surgical Pathology.

**Gulshan Yadav, MD**  
**Consultant Pathologist**