

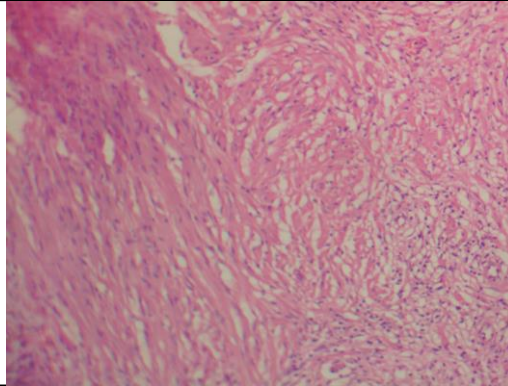
<b>Patient Name</b>	Ms. RAFEEQA 745 GULGAM	<b>Client Name</b>	Apollo Laboratories CC, Jammu & Kashmir	<b>Specimen Received</b>	29/02/2020
<b>Age/Sex</b>	45YRS/F			<b>Specimen Type</b>	Tissue
<b>Patient ID</b>	042002290072			<b>Collection Date</b>	29/02/2020
<b>Specimen ID</b>	MOLQ/B-501-20			<b>Report Date</b>	04/03/2020

## SURGICAL PATHOLOGY REPORT

### Sabaaceous Cyst on the Scapula Area

#### DIAGNOSIS

**SUGGESTIVE OF FOREIGN BODY TYPE OF REACTION**



#### SPECIMEN

Sabaaceous Cyst on the Scapula Area

#### GROSS

Received 2x1.6 cm grayish white tissue piece.

#### Microscopy

Section examined shows squamous lining with round to oval nucleus. Deeper tissue shows heavy inflammatory cells (lymphocytes, plasma cells, few polymorphs) with multinucleated giant cells and fibrocollagenous tissue.

No granuloma seen. No malignant cells seen.

**Note :** All biopsy specimen will be stored for 15 (fifteen) days, block and slides for 5 (five) years only from the time of receipt at the laboratory. No request ,for any of the above ,will be entertained after the due date.

#### Reference

- i) Rosai and Ackerman's Surgical Pathology.
- ii) Modern Surgical Pathology.

**Gulshan Yadav, MD**  
Consultant Pathologist