

Patient Name Mr. GAJ RAJ 48868
Age/Sex 68YRS/M
Patient ID 012003010138
Specimen ID MOLQ/B-509-20

Client Name Pushpanjali Hospital (Rewari)

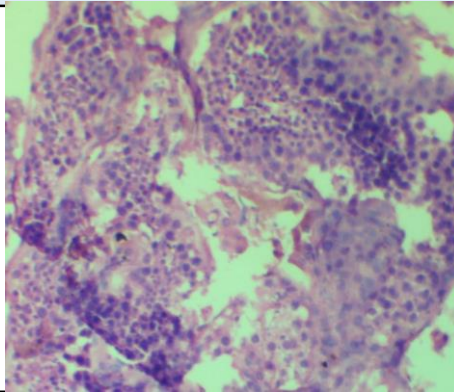
Specimen Received 01/03/2020
Specimen Type Tissue
Collection Date 01/03/2020
Report Date 04/03/2020

SURGICAL PATHOLOGY REPORT

Testicular Abscess

DIAGNOSIS

TESTICULAR ABSCESS



SPECIMEN

Testicular Abscess

GROSS

Received 4.5x3 cm testis with epididymus. Cut section shows necrotic changes.

Microscopy

Section examined shows effacement of testicular architecture with loss of mature and immature spermatogenic cells with large number of polymorphs, pus cells and lymphocytes.

No granuloma seen. No malignant cells seen.

Epididymus is unremarkable.

Note : All biopsy specimen will be stored for 15 (fifteen) days, block and slides for 5 (five) years only from the time of receipt at the laboratory. No request, for any of the above, will be entertained after the due date.

Reference

- i) Rosai and Ackerman's Surgical Pathology.
- ii) Modern Surgical Pathology.

A handwritten signature in black ink, appearing to read 'Gulshan'.

Gulshan Yadav, MD
Consultant Pathologist