

Patient Name Mr. ASHU
Age/Sex 13YRS/M
Patient ID 012003010078
Specimen ID MOLQ/B-508-20

Client Name Dr Heart Path Lab C/o
Navjeevan Hospital & Maternity Center

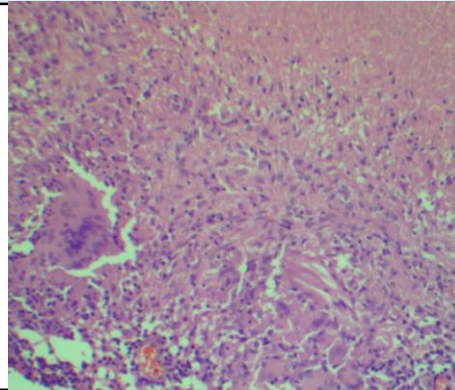
Specimen Received 01/03/2020
Specimen Type Tissue
Collection Date 01/03/2020
Report Date 04/03/2020

SURGICAL PATHOLOGY REPORT

Lymph Node (Right Neck)

DIAGNOSIS

TUBERCULAR LYMPHADENITIS



SPECIMEN

Lymph Node (Right Neck)

GROSS

Received multiple grayish white tissue piece, 3.5x3 cm in aggregate.


Microscopy

Section examined shows caseous necrosis with epithelioid cell granuloma. Presence of lymphocytes and few multinucleated giant cells. Section also shows fibrocollagenous tissue and blood vessels.

Note : All biopsy specimen will be stored for 15 (fifteen)days, block and slides for 5(five) years only from the time of receipt at the laboratory. No request ,for any of the above ,will be entertained after the due date.

Reference

- i) Rosai and Ackerman's Surgical Pathology.
- ii) Modern Surgical Pathology.


Gulshan Yadav, MD
Consultant Pathologist