

Patient Name Mrs. POONAM
Age/Sex 34YRS/F
Patient ID 012002290321
Specimen ID MOLQ/B-507/2020

Client Name Umkal Hospital

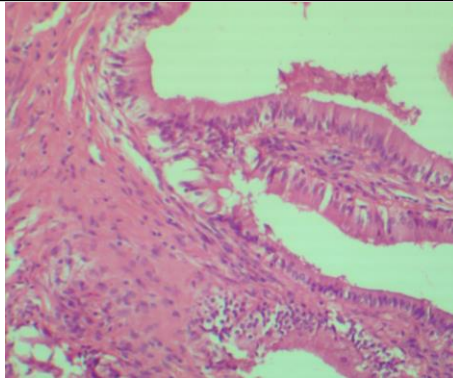
Specimen Received 29/02/2020
Specimen Type Tissue
Collection Date 29/02/2020
Report Date 04/03/2020

SURGICAL PATHOLOGY REPORT

Gall Bladder

DIAGNOSIS

CHOLECYSTITIS.



SPECIMEN

Gall Bladder

GROSS

Received 7x2.9cm long gall bladder already Cut open no stones. Wall thickness 0.4mm.


Microscopy

Section examined shows ulcerative mucosa and Rokitansky Aschoff sinus (irregularly shaped tubular structures lined by cuboidal lining epithelium with round to oval nucleus) with fibro collagenous tissue and inflammatory cells (lymphocytes).

Note : All biopsy specimen will be stored for 15 (fifteen)days, block and slides for 5(five) years only from the time of receipt at the laboratory. No request ,for any of the above ,will be entertained after the due date.

Reference

- i) Rosai and Ackerman's Surgical Pathology.
- ii) Modern Surgical Pathology.


Gulshan Yadav, MD
Consultant Pathologist