

Patient Name Mrs. SEEMA
Age/Sex 29YRS/F
Patient ID 012002290311
Specimen ID MOLQ/B-506-20

Client Name Chauhan Hospital

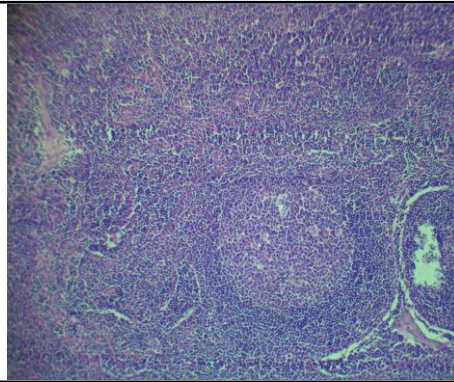
Specimen Received 03/02/2020
Specimen Type Tissue
Collection Date 03/02/2020
Report Date 05/03/2020

SURGICAL PATHOLOGY REPORT

? Appendix Koch

DIAGNOSIS

GRANULOMATOUS LESION (TUBERCULAR PATHOLOGY STRONGLY SUSPICIOUS)



SPECIMEN

? Appendix Koch

GROSS

Received 3.5x5 cm greyish white tissue piece.

Microscopy

Section examined shows lymphoid follicles with epithelioid cells with granuloma formation along with multinucleated giant cells.

Note : All biopsy specimen will be stored for 15 (fifteen) days, block and slides for 5 (five) years only from the time of receipt at the laboratory. No request, for any of the above, will be entertained after the due date.

Reference

- i) Rosai and Ackerman's Surgical Pathology.
- ii) Modern Surgical Pathology.

A handwritten signature in black ink, appearing to read 'Gulshan'.

Gulshan Yadav, MD
Consultant Pathologist