

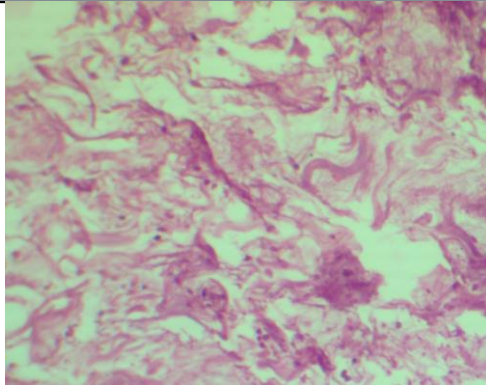
<b>Patient Name</b>	Mr. PUSHPENDER	<b>Client Name</b>	North Delhi Diagnostic	<b>Specimen Received</b>	29/02/2020
<b>Age/Sex</b>	38YRS/M			<b>Specimen Type</b>	Tissue
<b>Patient ID</b>	012002290230			<b>Collection Date</b>	29/02/2020
<b>Specimen ID</b>	MOLQ/B-505-20			<b>Report Date</b>	04/03/2020

## SURGICAL PATHOLOGY REPORT

### Fissure in anorectal region

#### DIAGNOSIS

**NON-SPECIFIC INFLAMMATION.**



#### **SPECIMEN**

Fissure in anorectal region

#### **GROSS**

Received 1x1 cm grayish white tissue piece.


#### **Microscopy**

Section examined shows squamous lining epithelium with round nucleus with ulcerations. Deeper fibrocollagenous tissue and inflammatory cells. No granuloma seen. No malignant cells seen.

**Note :** All biopsy specimen will be stored for 15 (fifteen)days, block and slides for 5(five) years only from the time of receipt at the laboratory. No request ,for any of the above ,will be entertained after the due date.

#### **Reference**

- i) Rosai and Ackerman's Surgical Pathology.
- ii) Modern Surgical Pathology.

  
**Gulshan Yadav, MD**  
**Consultant Pathologist**