

Patient Name Mr. abhay
Age/Sex 22YRS/M
Patient ID 012002290198
Specimen ID MOLQ/B-504/2020

Client Name Path Star Diagnostic

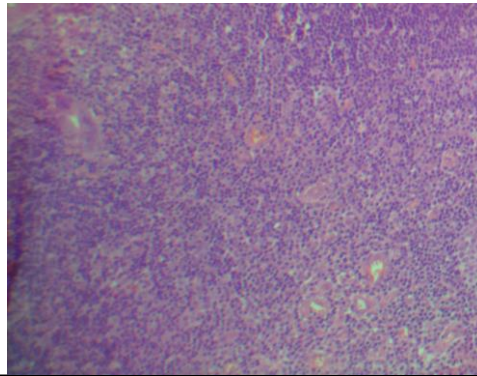
Specimen Received 04/02/2020
Specimen Type Tissue
Collection Date 04/02/2020
Report Date 05/03/2020

SURGICAL PATHOLOGY REPORT

Appendix

DIAGNOSIS

ACUTE APPENDICITIS



SPECIMEN

Appendix

GROSS

Received 5.2x2.0cm long appendix. Cut section shows feco-lith.

Microscopy

Section examined shows autolytic changes with lymphoid follicles with ulcerative mucosa. Deeper tissue shows inflammatory cells (polymorphs and lymphocytes). No granuloma seen. No malignant cells seen.

Note : All biopsy specimen will be stored for 15 (fifteen)days, block and slides for 5(five) years only from the time of receipt at the laboratory. No request ,for any of the above ,will be entertained after the due date.

Reference

- i) Rosai and Ackerman's Surgical Pathology.
- ii) Modern Surgical Pathology.

A handwritten signature in black ink, appearing to read 'Gulshan'.

Gulshan Yadav, MD
Consultant Pathologist