

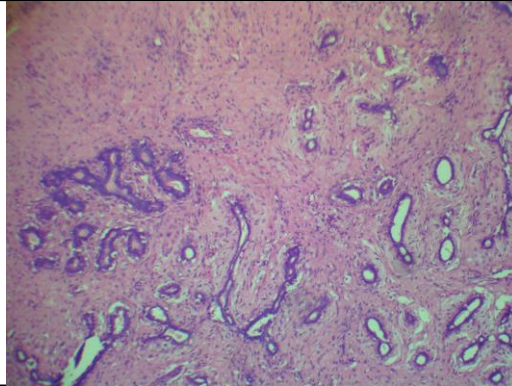
| | | | | | |
|---------------------|-------------------------|--------------------|---|--------------------------|------------|
| Patient Name | Miss. SHAYSTA ASHTINGOO | Client Name | City Medical Laboratory, Jammu & Kashmir | Specimen Received | 28/02/2020 |
| Age/Sex | 16YRS/F | | | Specimen Type | Tissue |
| Patient ID | 042002280114 | | | Collection Date | 28/02/2020 |
| Specimen ID | MOLQ/B-496-20 | | | Report Date | 03/03/2020 |

SURGICAL PATHOLOGY REPORT

Fibroadenoma Right Breast

DIAGNOSIS

BENIGN BREAST LESION



SPECIMEN

Fibroadenoma Right Breast

GROSS

Received 2.5x2 cm greyish white tissue piece.

Microscopy


Section examined shows ducts (few cystically dilated) with cuboidal epithelium with small round nucleus surrounded by fibro collagenous tissue.

No granuloma seen. No malignant cells seen.

Note : All biopsy specimen will be stored for 15 (fifteen) days, block and slides for 5 (five) years only from the time of receipt at the laboratory. No request ,for any of the above ,will be entertained after the due date.

Reference

- i) Rosai and Ackerman's Surgical Pathology.
- ii) Modern Surgical Pathology.


Gulshan Yadav, MD
Consultant Pathologist