

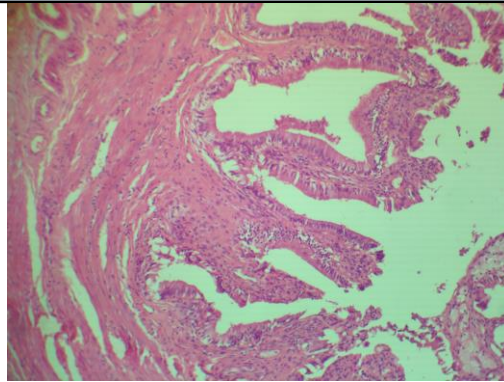
Patient Name	Ms. SHAHZADA W/O FAROOQ AHMAD/WUYAN	Client Name	A-One Collection Centre, Jammu & Kashmir	Specimen Received	28/02/2020
Age/Sex	45YRS/F			Specimen Type	Tissue
Patient ID	042002280080			Collection Date	28/02/2020
Specimen ID	MOLQ/B-494-20			Report Date	03/03/2020

SURGICAL PATHOLOGY REPORT

Gall Bladder

DIAGNOSIS

CHOLECYSTITIS AND CHOLELITHIASIS.



SPECIMEN

Gall Bladder

GROSS

Received 7x2.9 cm long gall bladder. Cut section shows tiny stones.


Microscopy

Section examined shows ulcerative mucosa and Rokitansky-Aschoff sinus (irregularly shaped tubular structures lined by cuboidal lining epithelium with round to oval nucleus) with fibrocollagenous tissue and inflammatory cells (lymphocytes).

Note : All biopsy specimen will be stored for 15 (fifteen) days, block and slides for 5 (five) years only from the time of receipt at the laboratory. No request, for any of the above, will be entertained after the due date.

Reference

- i) Rosai and Ackerman's Surgical Pathology.
- ii) Modern Surgical Pathology.


Gulshan Yadav, MD
Consultant Pathologist